

Back To Chiropractic CE Seminars

MRI Lumbar Spine ~ 6 Hours


Welcome to Back To Chiropractic Online CE exams:

**This course counts toward your California Board of Chiropractic Examiners CE.
(also accepted in other states, check our website or with your Chiropractic State Board)**

**The California Board requires that you complete all of your CE hours BEFORE
the end of your Birthday month. We recommend that you send your chiropractic
license renewal form and fee in early to avoid any issues.**

COPYRIGHT WARNING

The copyright law of the United States (Title 17, United States Code) governs the making of photocopies or other reproductions of copyrighted material. Under certain conditions specified in the law, libraries and archives are authorized to furnish a photocopy or other reproduction. One of these specified conditions is that the photocopy or reproduction is not to be "used for any purpose other than private study, scholarship, or research." If a user makes a request for, or later uses, a photocopy or reproduction for purposes in excess of "fair use," that user may be liable for copyright infringement. This site reserves the right to refuse to accept a copying order if, in its judgment, fulfillment of the order would involve violation of the copyright law.



Exam Process: Please read all instructions before starting!

- 1. You must register/pay first. If you haven't, please return to: backtochiropractic.net**
- 2. Open a new window or a new internet tab & drag it so it's side-by-side next to this page.**
- 3. On the new window or new tab you just opened, go to: backtochiropractic.net website.**
- 4. Go directly to the Online section. DON'T register again.**
- 5. Click on the Exam for the course you want to take. No passwords needed.**
- 6. Follow the Exam instructions.**
- 7. Upon passing the exam you'll be able to immediately download your certificate, and it'll also be emailed to you. If you don't pass, you can repeat the exam at no charge.**

Please retain the certificate for 4 years.

If you get audited and lose your records, I'll have a copy.

I'm always a phone call away... 707.972.0047 or email: marcusstrutzdc@gmail.com

Marcus Strutz, DC

Back To Chiropractic CE Seminars



MRI of the Lumbar Spine: For the Chiropractic Clinician

Jennifer Pedley, MS, DC, CCSP, DACBR

OBJECTIVE

- ▶ This will not make you into a radiologist;)
 - ▶ This will familiarize you with the anatomy on the *MRI images, and familiarize you with the terminology commonly used on the radiology reports.
 - ▶ This will give you guidance and confidence in treating your patient with disc pathology.
-
- ▶ *MRI=Magnetic Resonance Imaging

Our To Do List

- ▶ When to send patient's out for MRI: Criteria for ordering MRI.
- ▶ How does xrays, MRI and CT differ?
- ▶ Ordering MRI: With or without contrast
- ▶ Anatomy shown on the sagittal, parasagittal and axial images
- ▶ Nomenclature of disc pathology
 - ▶ See Article listed at the end of the lecture
- ▶ What is the disc doing to the nerves.....there are 2 types of nerve roots!
- ▶ How does the information on MRI affect my treatment plan/protocol?

Criteria for Ordering MRI

- ▶ Some indicators:
 - ▶ Neurological deficit
 - ▶ Radiculopathy with no response to 4 weeks of *conservative treatment
 - ▶ Spinal stenosis: spinal canal or neural foramina stenosis
 - ▶ Spinal fracture: compression fracture, pathologic versus non-pathologic
 - ▶ Degenerative disc disease with no response to 4 week treatment
 - ▶ Recurrent symptoms after spinal surgery
 - ▶ Clinically/Radiographic evidence of: infection, cancer, metastatic disease.
- ▶ *Note: Conservative treatment may include chiropractic, physical therapy, acupuncture, massage therapy, etc.

What is the difference between Xray, MRI and CT (brief list):

- ▶ Xray and CT show bony detail
 - ▶ Radiation (greater with CT)
 - ▶ Fractures/dislocations, *Acute* brain trauma and bleeds, chest, abdomen, pelvic regions.
- ▶ Generally speaking, MRI shows **soft tissue and what's inside the bone.**
 - ▶ No radiation
 - ▶ *Subacute to chronic* brain trauma and bleeds; tumors/lesions of bone and soft tissue; and spine and extremities.
 - ▶ Stress fractures; Impaction fractures and bone contusions
 - ▶ Disc; Spinal cord
 - ▶ Tendons, ligaments, labrum, meniscus, etc.

MRI- With or without contrast?

- ▶ Most patients do not require gadolinium contrast
- ▶ Most common reasons to add contrast to MR study
 - ▶ **Intravenous Gadolinium Contrast**
 - ▶ Prior spinal surgery due to epidural fibrosis which is scar tissue in the spinal canal-- scar tissue will absorb contrast.
 - ▶ Tumor/mass and Infection detected clinically or on radiographs.

MRI- With or without contrast?

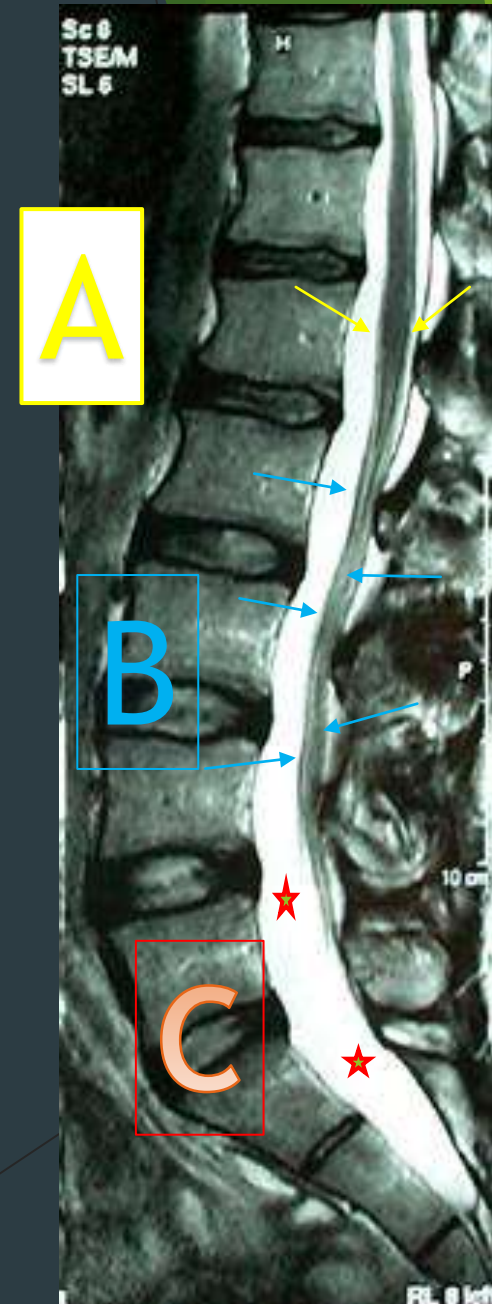
- ▶ **Arthrography contrast:** gadolinium contrast solution injected into the joint capsule
 - ▶ Rule out labral tear of the hip
 - ▶ Previous meniscectomy with a second knee injury.
- ▶ Most of the time, shoulders do not need contrast.
 - ▶ Scenario: Initial shoulder MR study detected no labral tear and/or no tears of the tendons. The clinician is suspecting a labral tear and/or tendon tear, and patient continues to not respond to care. Now, the clinician should order a repeated MRI *with arthrography*. Sometimes (very rare), these tears can hide 😊

Anatomy on Sagittal images

- ▶ Distal spinal cord=Conus medullaris
- ▶ Cauda equina
- ▶ Cerebrospinal fluid
- ▶ Intervertebral discs
- ▶ Vertebral bodies
- ▶ Spinous processes
- ▶ Ligaments
 - ▶ Anterior longitudinal ligament-ALL
 - ▶ Posterior longitudinal ligament-PLL
 - ▶ Ligamentum flavum
 - ▶ Interspinous ligaments

Anatomy on Mid-Sagittal images

- ▶ **A.** Distal Cord is the **Conus medullaris** (**yellow arrows**): Typically terminates at the level of T12, L1 or L2.
- ▶ **B.** Cauda equina (**blue arrows**): Nerve roots extending from the conus medullaris.
- ▶ **C.** Cerebrospinal Fluid (**red star**): Inside the spinal canal, normal fluid surrounding the spinal cord, conus medullaris and cauda equina.



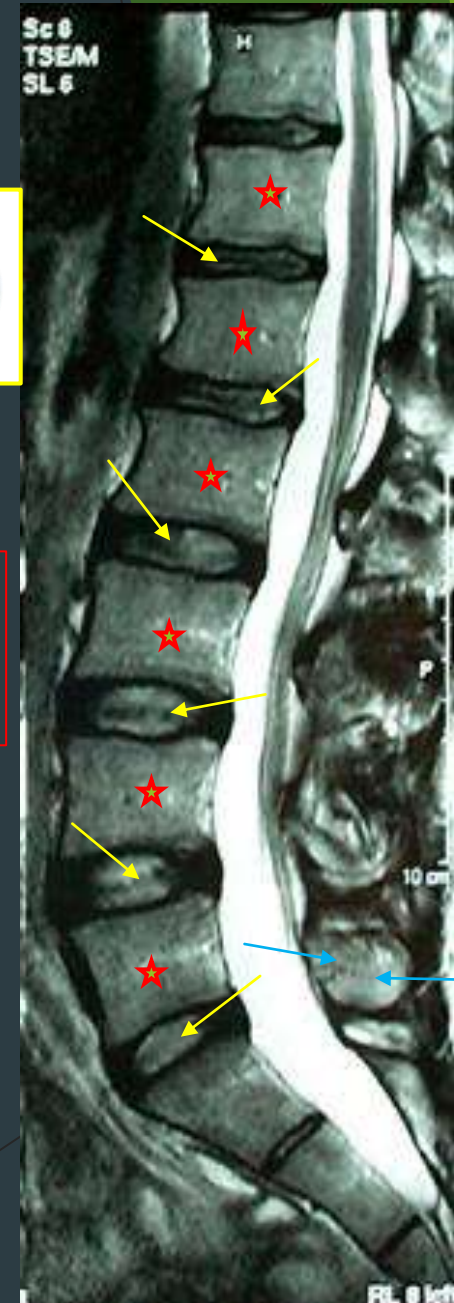
Anatomy on Mid-Sagittal images

- ▶ Central canal- looking for stenosis and/or lesions in the canal.
- ▶ **D.** Intervertebral disc (**yellow arrows**)
- ▶ **E.** Vertebral bodies (**red star**)
- ▶ **F.** Spinous processes (**blue arrows**)-
 - ▶ There is slice asymmetry, therefore, we are not seeing all of the spinous processes above at each level, within this particular sagittal slice/image.

D

E

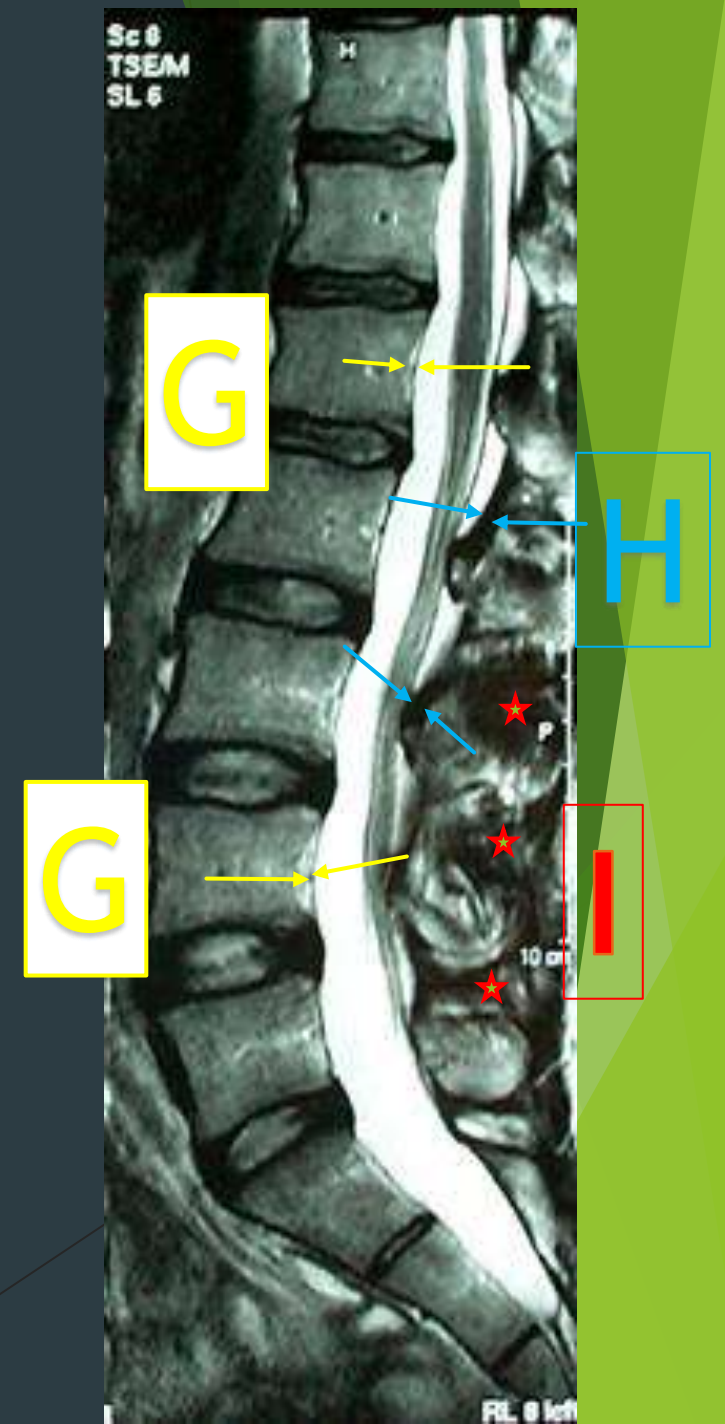
F



Anatomy on Mid-Sagittal images

Ligaments

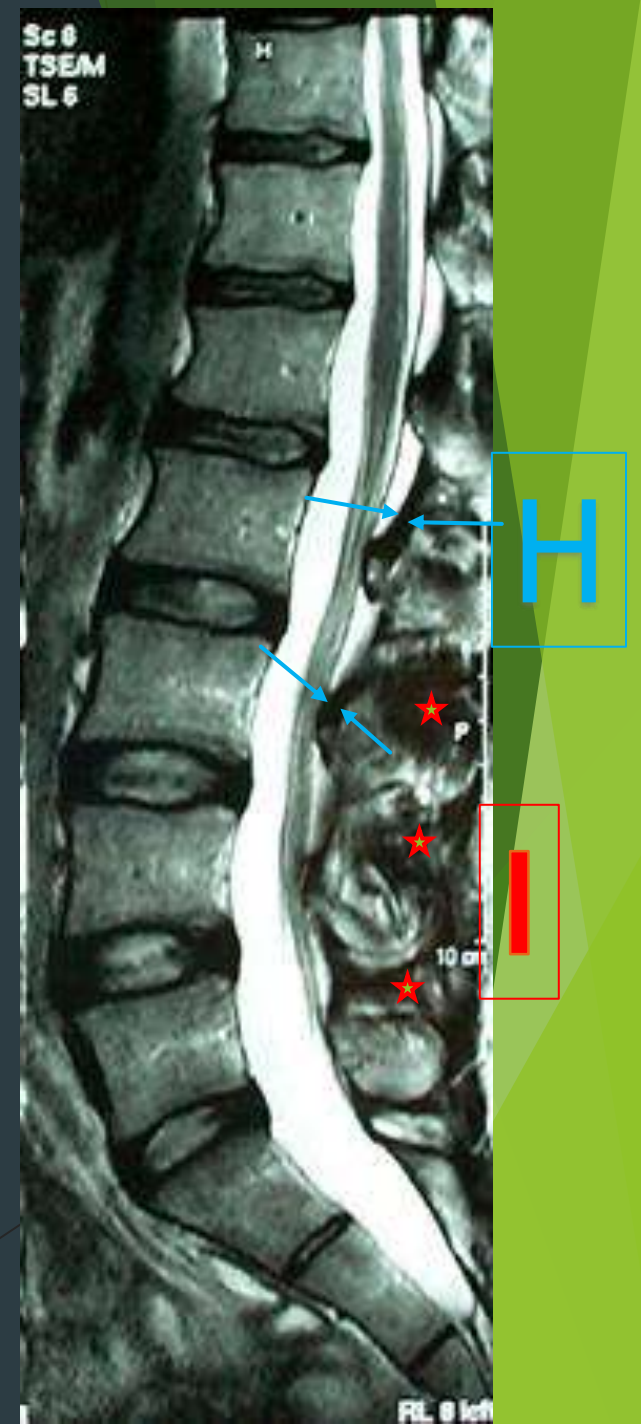
- ▶ Anterior longitudinal ligament (ALL)- when normal, you cannot see the ALL along the anterior aspect of the vertebral bodies and disc levels.
- ▶ **G.** Posterior longitudinal ligament (PLL) (**yellow arrows**)- normal, very thin ligament.



Anatomy on Mid-Sagittal images

Ligaments

- ▶ **H.** Ligamentum flavum (**blue arrows**)- a thin black line along the anterior aspect of the lamina.
- ▶ **I.** Interspinous ligaments (**red star**)- ligaments between each spinous process

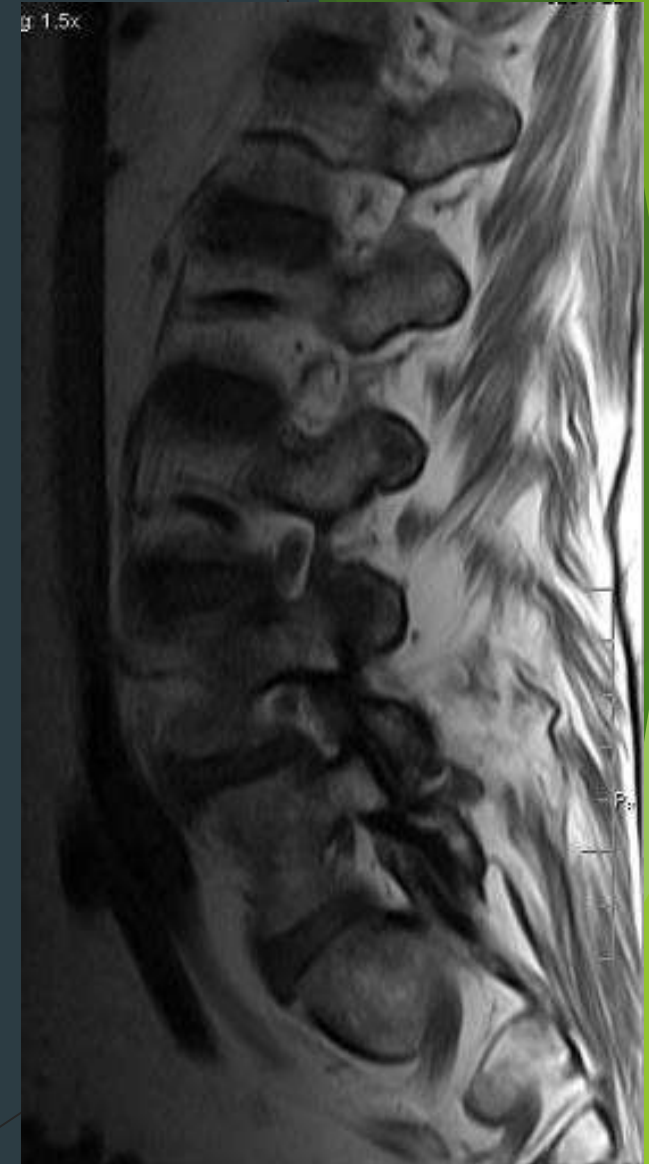

Anatomy on the Right & Left Parasagittal images

- ▶ Pedicles
- ▶ Exiting nerve roots & Neural foramina
- ▶ Facet joints
- ▶ Pars interarticularis

Right/Left Parasagittal Images

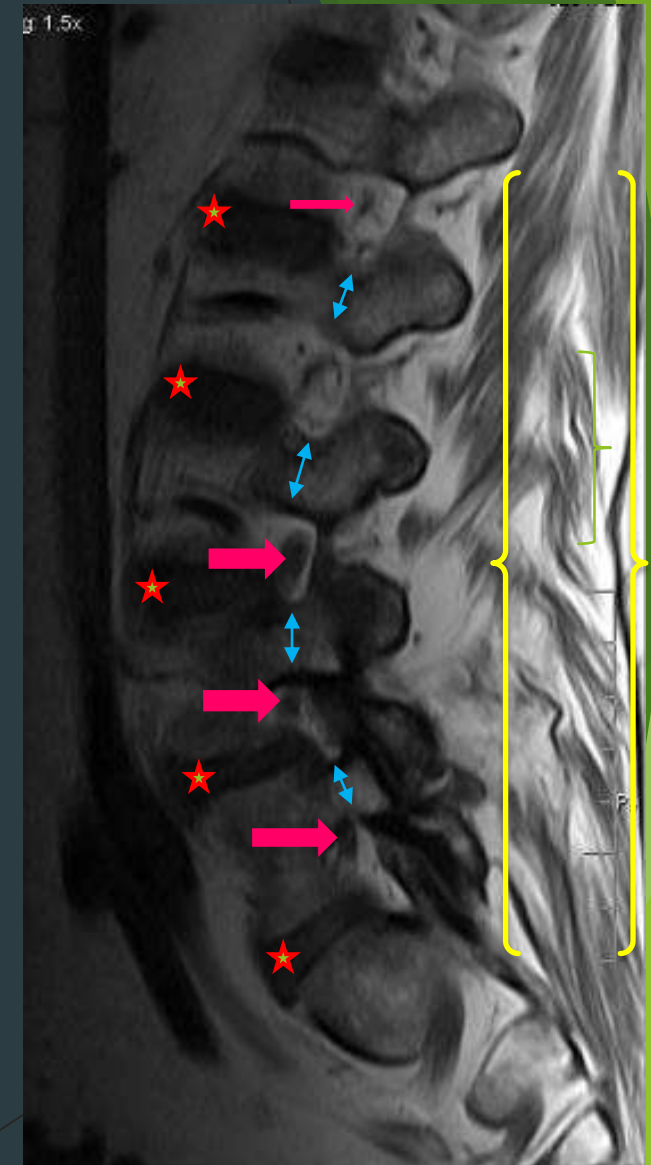
- ▶ **Parasagittal images allow to evaluate the following:**
 - ▶ Neural foramina- to evaluate for stenosis (Grading stenosis by mild, moderate or severe, while dividing into thirds);
 - ▶ Disc and facet joints- to see what they are doing to the exiting nerve roots, such as encroaching, effacing/abutting, or compressing the nerve roots.
 - ▶ Pars interarticularis- to evaluate for defects or stress fracture/reactive bone changes.



Reminder: The exiting nerve root exits 'below' in the lumbar spine. Example, at the L3-L4 disc level, the exiting nerve root in the neural foramina would be L3. The L4-L5 disc level, the exiting nerve roots in the neural foramina would be L4.

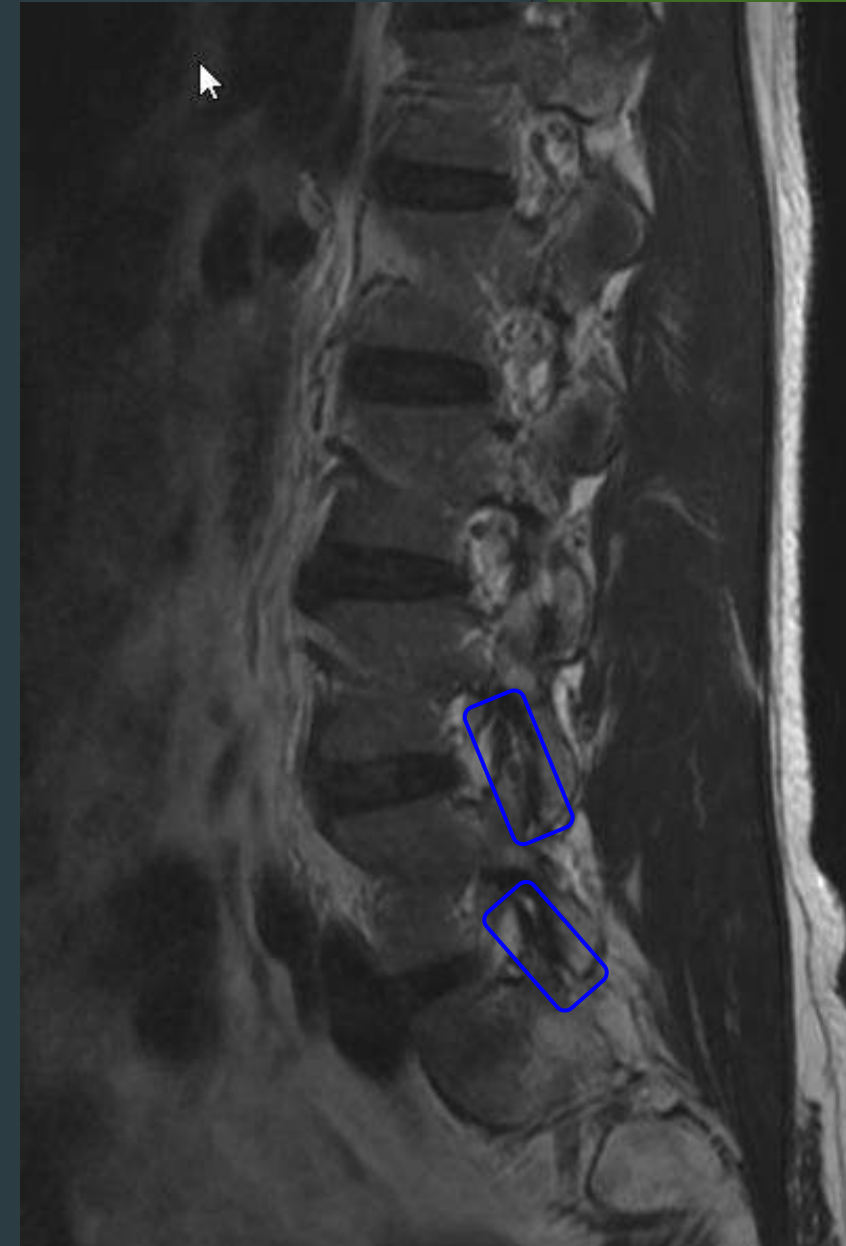
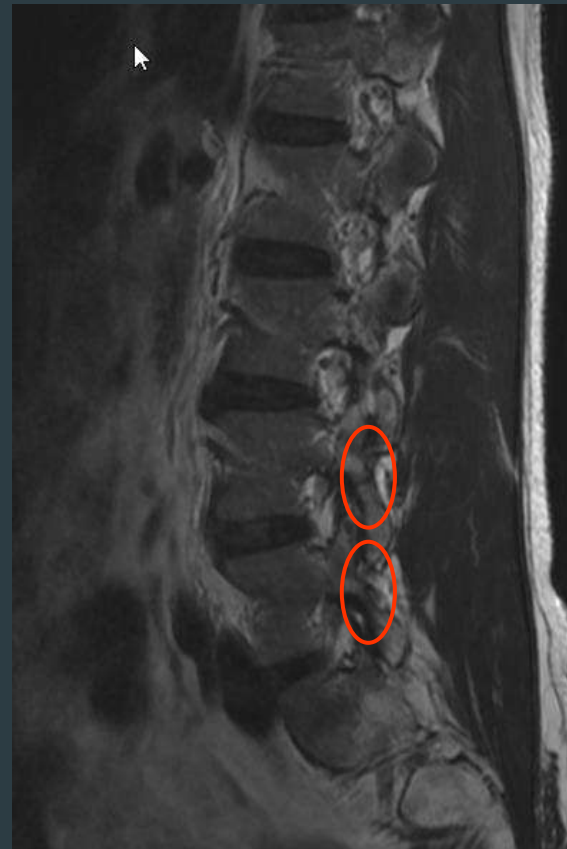Anatomy on the Right or Left Parasagittal Images

- ▶ J. Pedicles (blue double arrows)
- ▶ K. Exiting nerve roots (pink arrows)- is the black dot within the neural foramina.
- ▶ Disc= ★
- ▶ Posteriorly, normal muscle with normal fat striations= { }



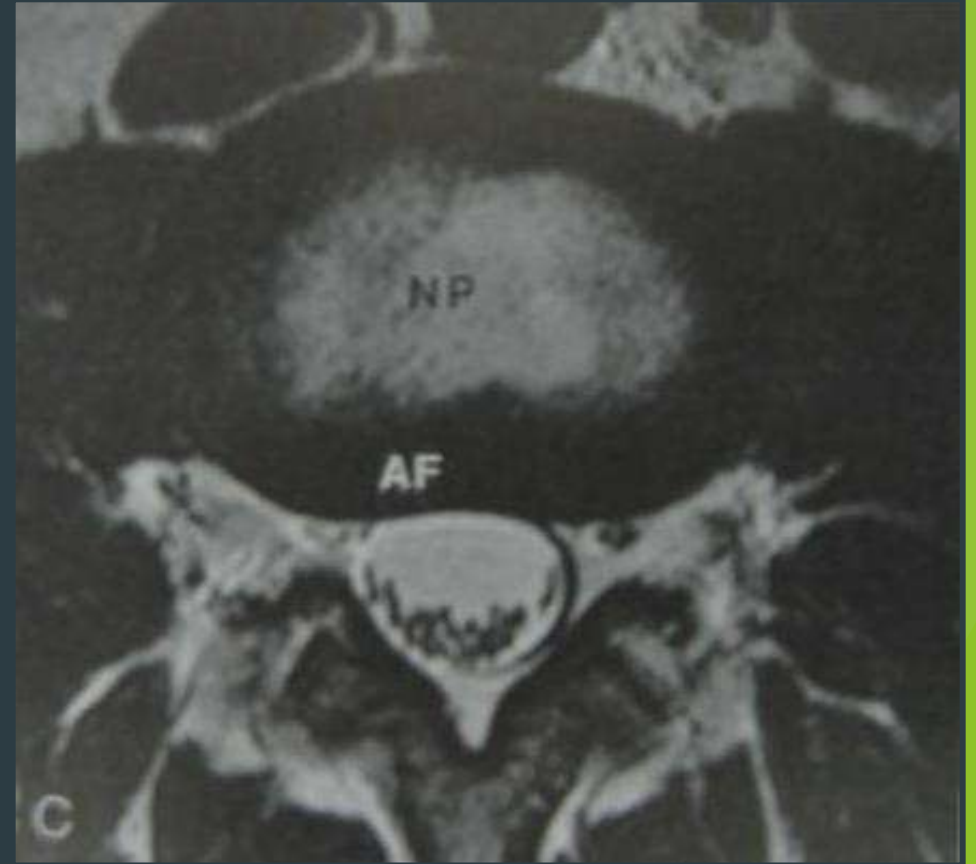
Anatomy on the Right or Left Parasagittal Images

- ▶ Facet joints- blue rectangle
- ▶ Pars interarticularis- orange circle



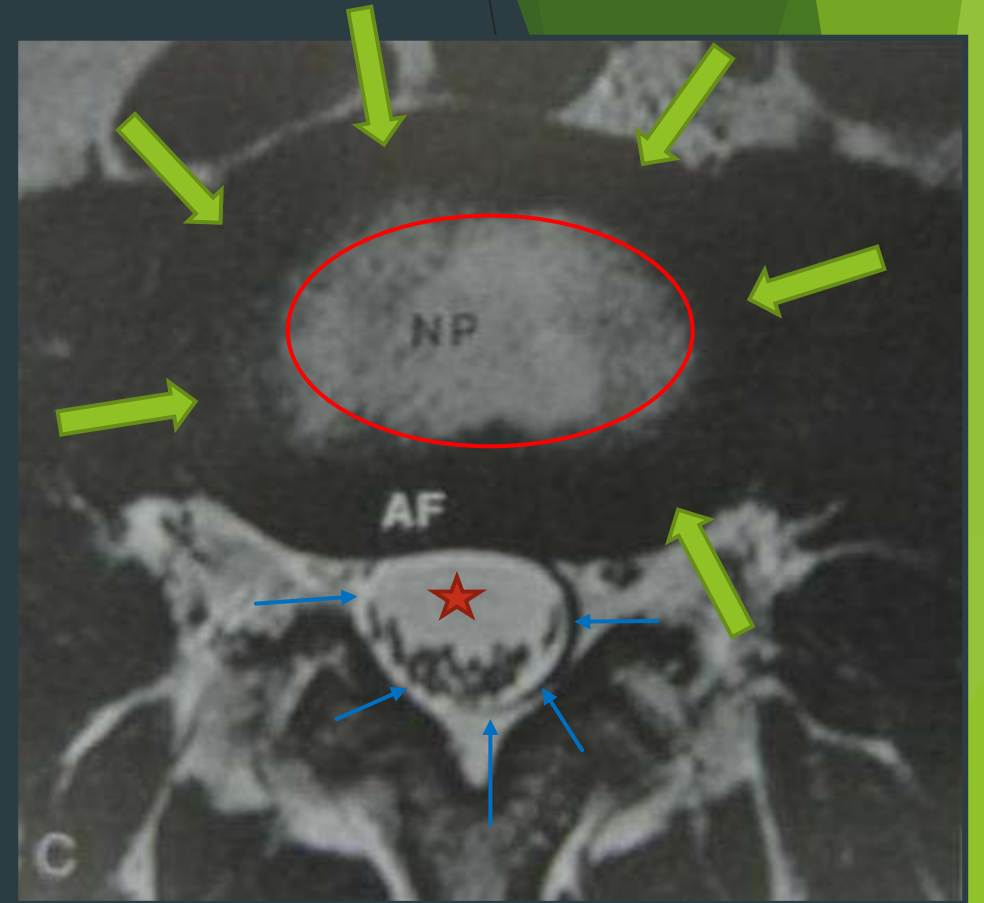
Anatomy on Axial Images

- ▶ Intervertebral disc: Nucleus pulposus & Annulus fibrosus
- ▶ Thecal Sac
- ▶ Epidural fat
- ▶ Cauda equina
- ▶ Cerebrospinal fluid
- ▶ Descending nerve roots
- ▶ Exiting nerve roots
- ▶ Lamina & Ligamentum flavum
- ▶ Facet joints
- ▶ Spinous process
- ▶ Iliopsoas, dorsal musculature; Aorta/iliac arteries



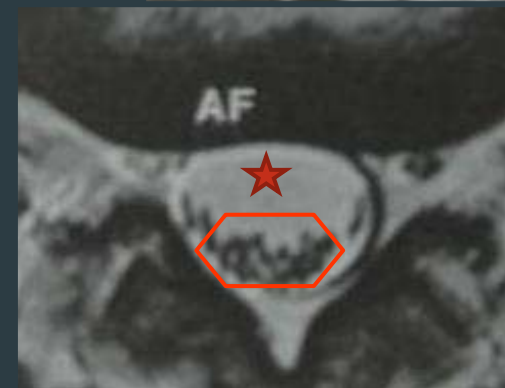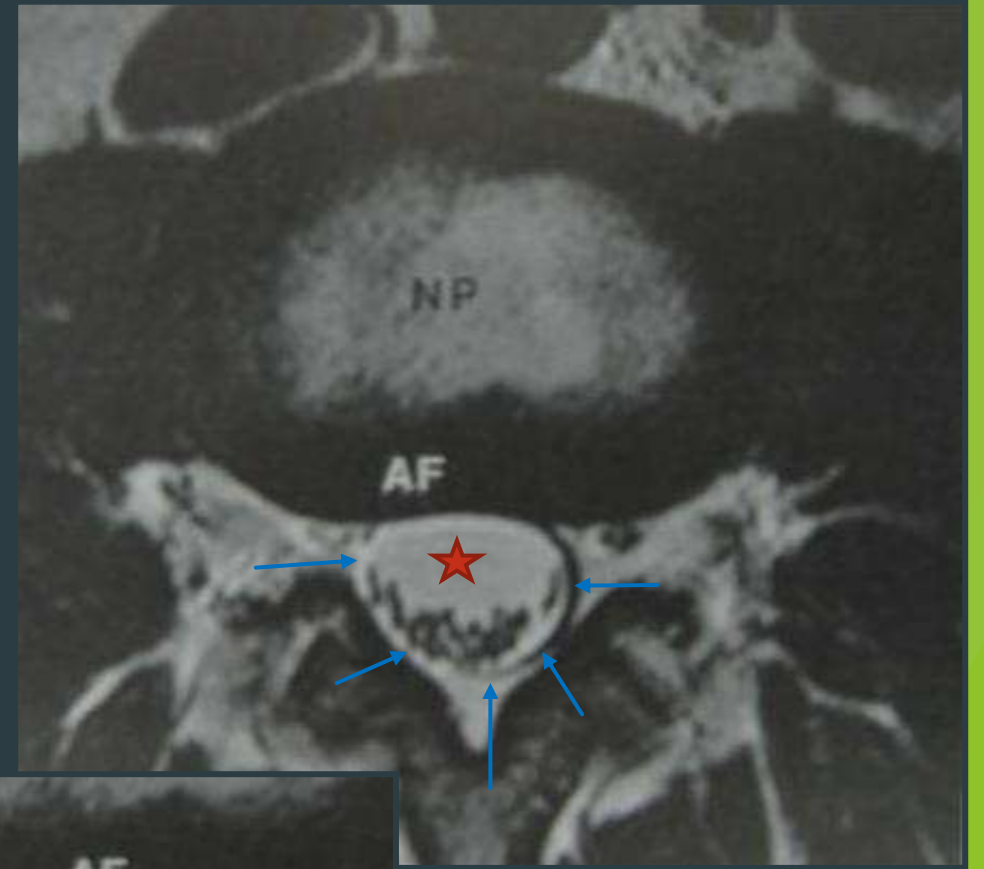
Anatomy on Axial Images

- ▶ Intervertebral disc:
 - ▶ Nucleus pulposus (NP)- Red circle
 - ▶ Annulus fibrosus (AF)- Green arrows
- ▶ Thecal sac (blue arrows)- Thin dura lining, contains the cauda equina and cerebrospinal fluid
- ▶ Cerebrospinal fluid= ★ The fluid is contained by the thecal sac.



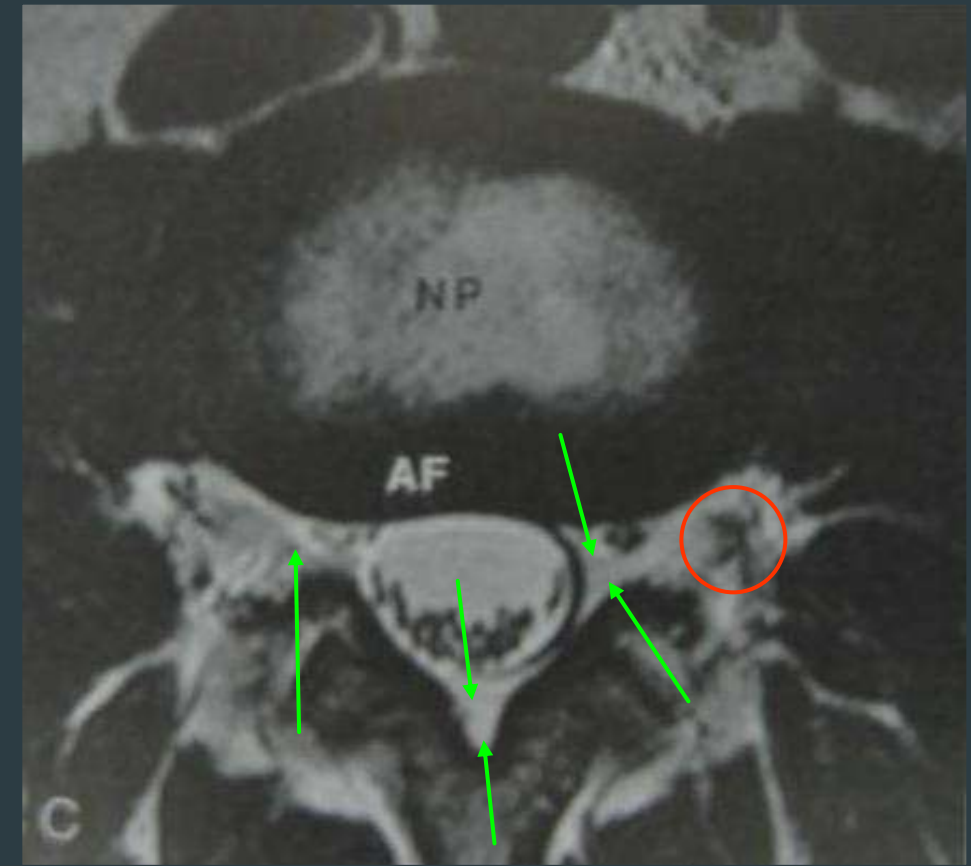
Anatomy on Axial Images

- ▶ Thecal sac (blue arrows)- Thin dura lining, contains the cauda equina and cerebrospinal fluid
★
- ▶ Cerebrospinal fluid= The fluid is contained by the thecal sac.
- ▶ Cauda equina= All of the black dots (orange hexagon) within the thecal sac.



Anatomy on Axial Images

- ▶ Epidural fat (**green arrows**)-bright signal surrounding the thecal sac and nerve roots. Fat is bright on T2 and T1 weighted images
- ▶ Exiting nerve roots (**red outline**)- sometimes appears oval or squiggle line on the axial images, posterolaterally.

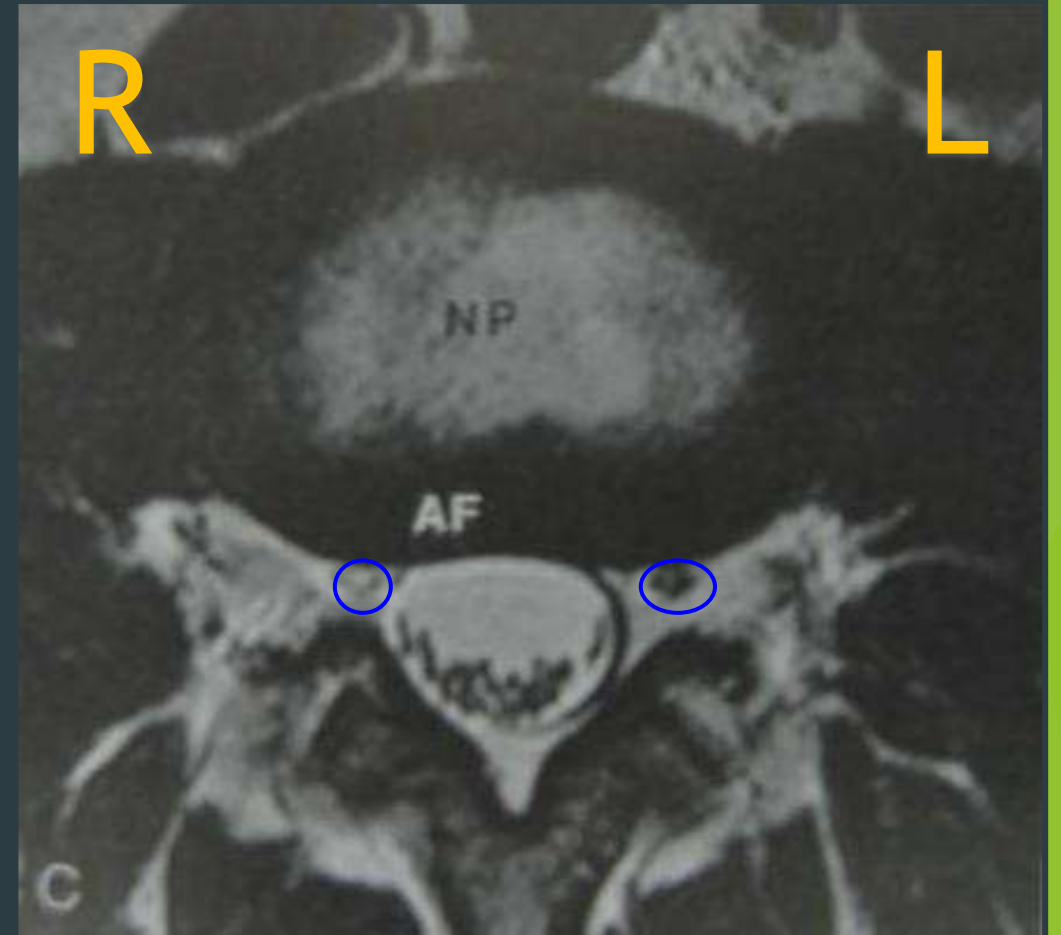


REMINDER

Reminder: The parasagittal images are the best images to evaluate the exiting nerve roots, not the axial images.

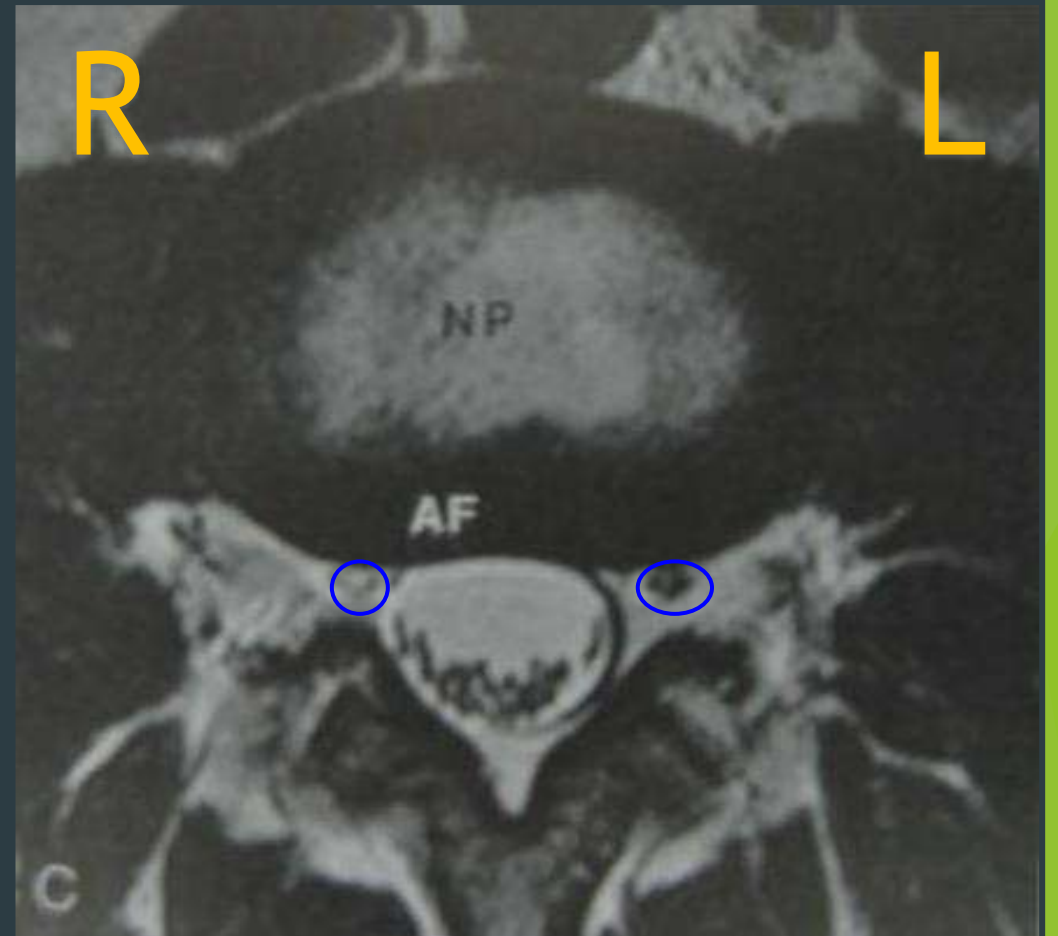
Anatomy on Axial Images

- ▶ Descending nerve roots- (blue circle). The black dot is the typical presentation on the axial images.
- ▶ There is some slice asymmetry involving the right descending nerve root, catching some of the epidural fat and nerve root.
- ▶ NOTE: PATIENT'S RIGHT SIDE IS ON YOUR VIEWING LEFT; PATIENT'S LEFT SIDE IS ON YOUR VIEWING RIGHT.



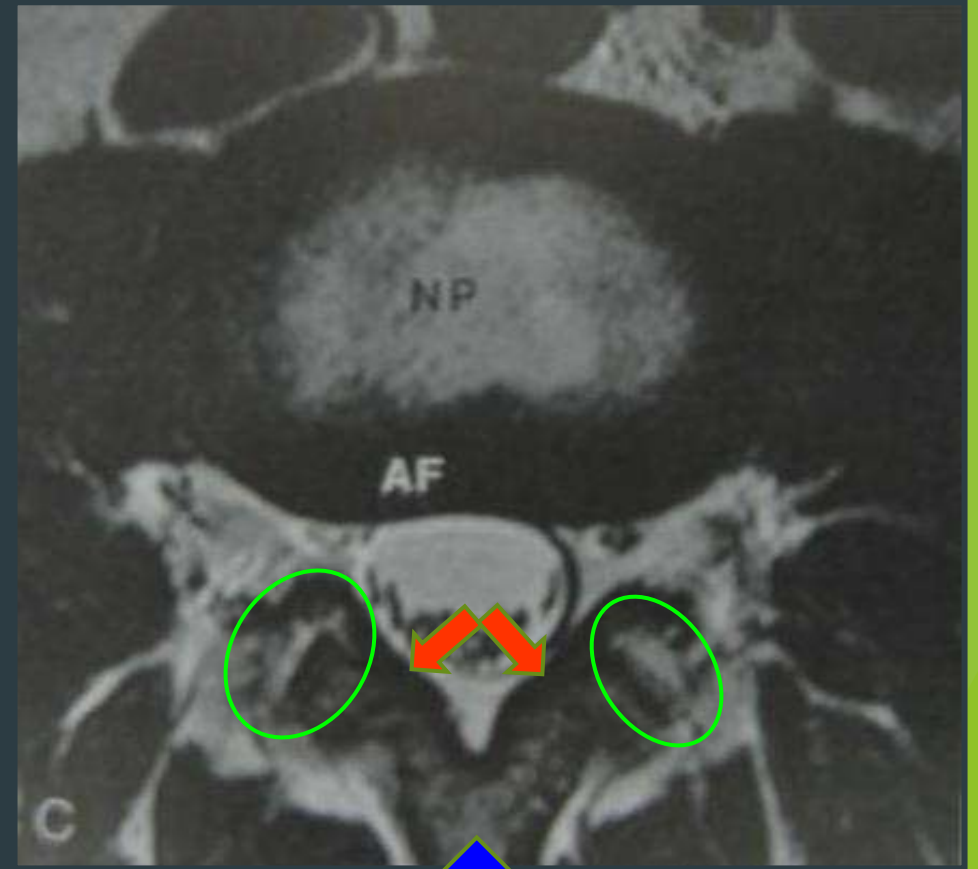
Anatomy on Axial Images

- ▶ Descending nerve roots- (blue circle).
 - ▶ Also known as Transiting nerve root or Traversing nerve root.
- ▶ NOTE: PATIENT'S RIGHT SIDE IS ON YOUR VIEWING LEFT; PATIENT'S LEFT SIDE IS ON YOUR VIEWING RIGHT.



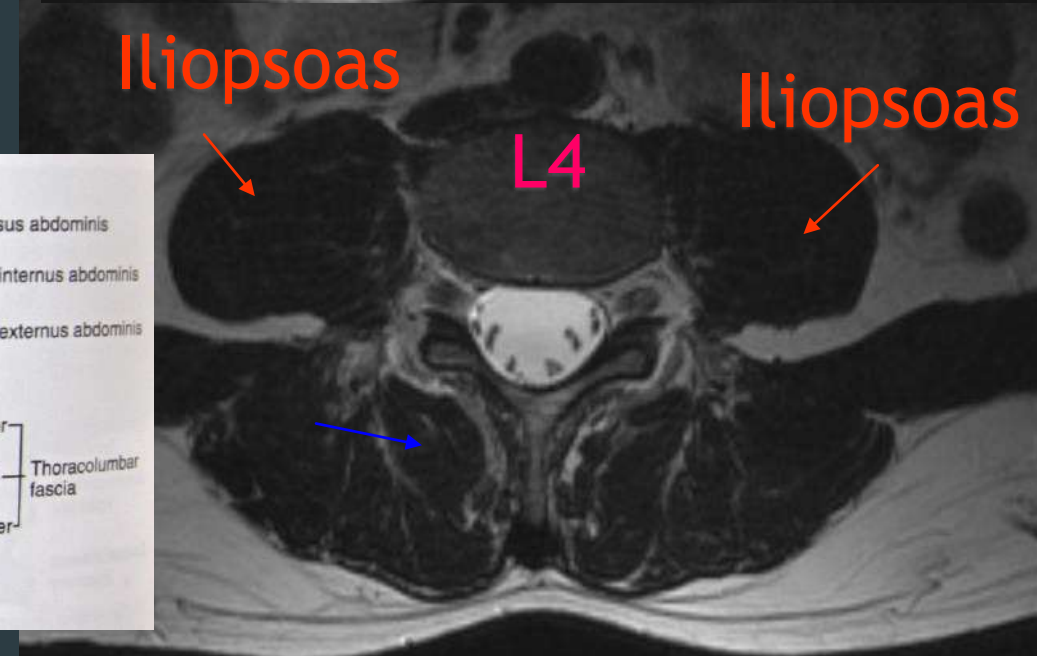
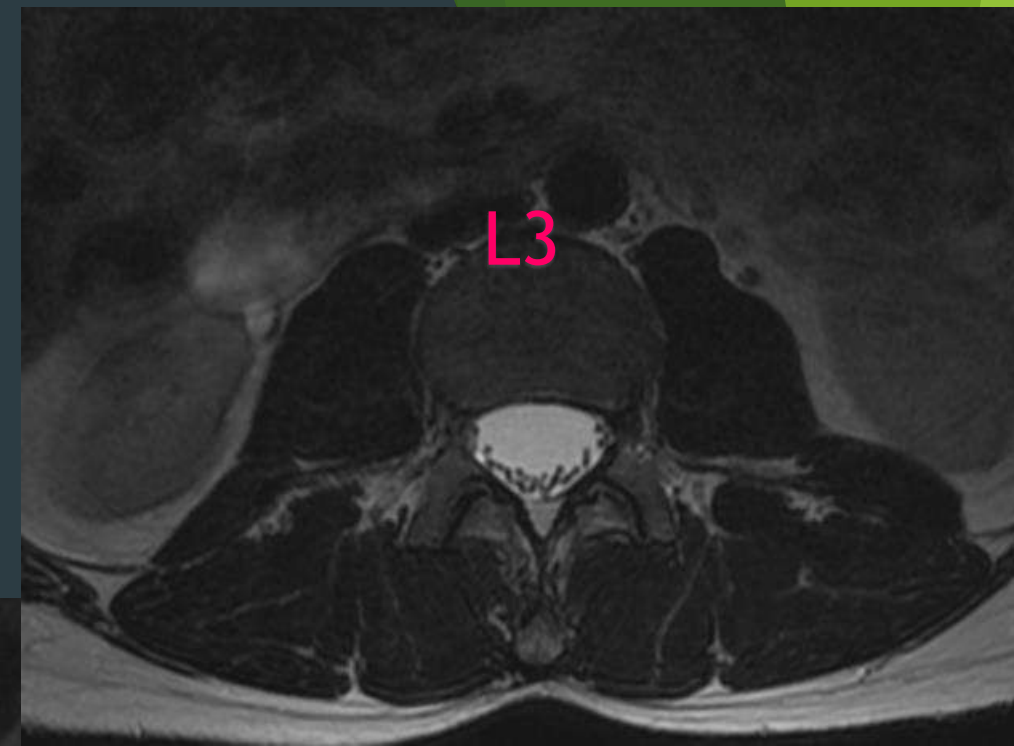
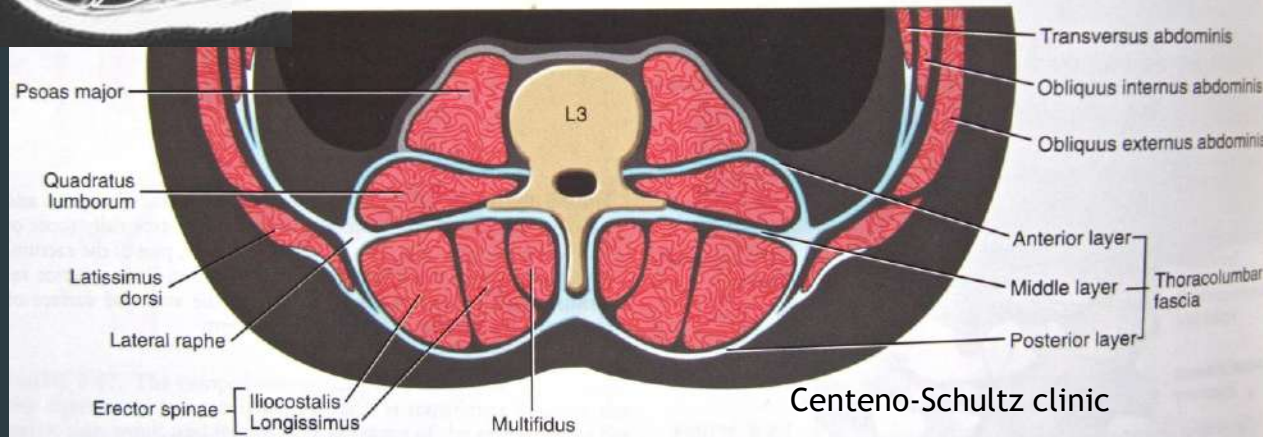
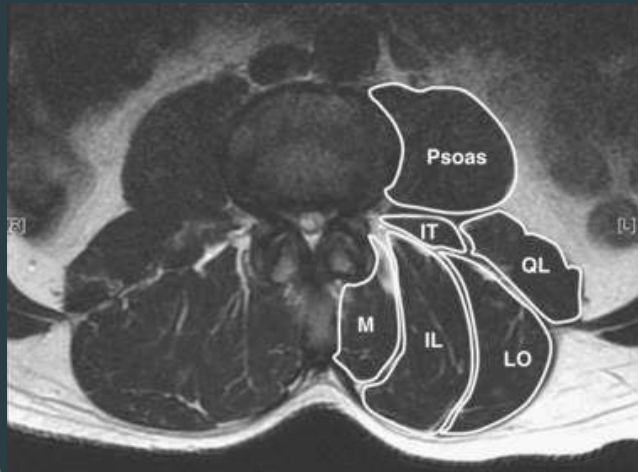
Anatomy on Axial Images

- ▶ Lamina & Ligamentum flavum- (**orange arrows**)
 - ▶ Ligamentum flavum is the black thin 'line' along the anterior margins of the lamina.
- ▶ Facet joints- (**green circle outline**)
 - ▶ These are normal facet joints....we will see more examples😊
- ▶ Spinous process- (**blue arrow**)



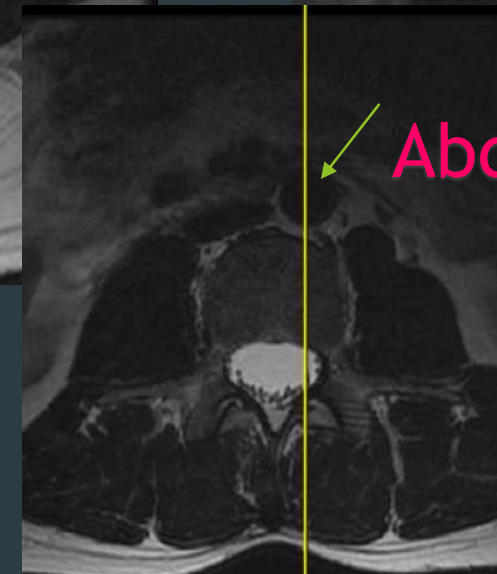
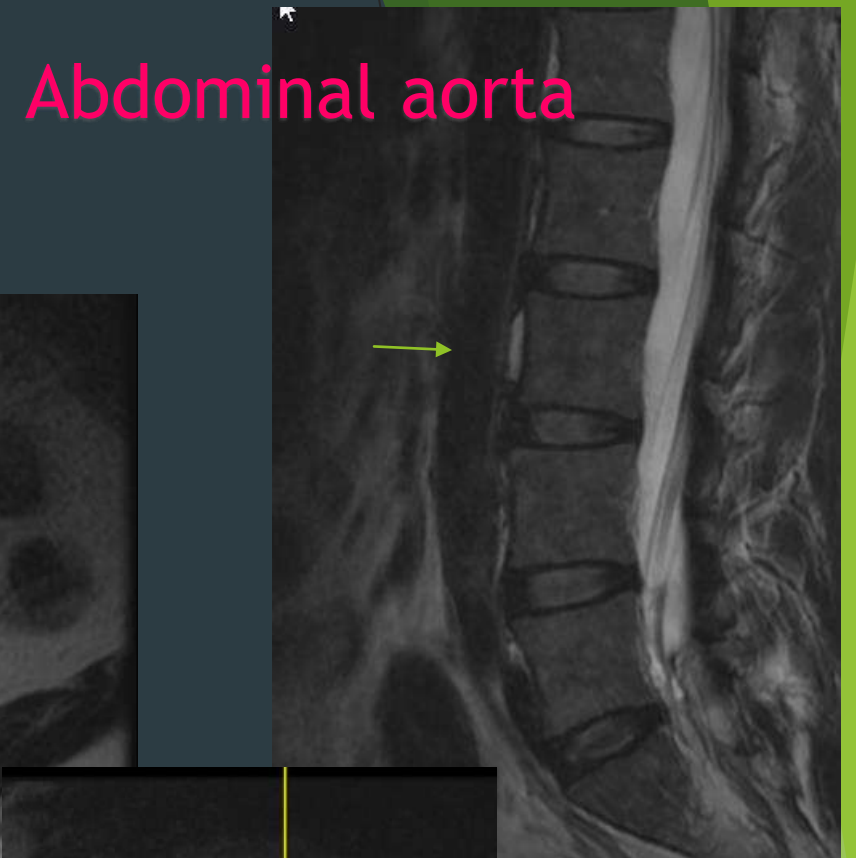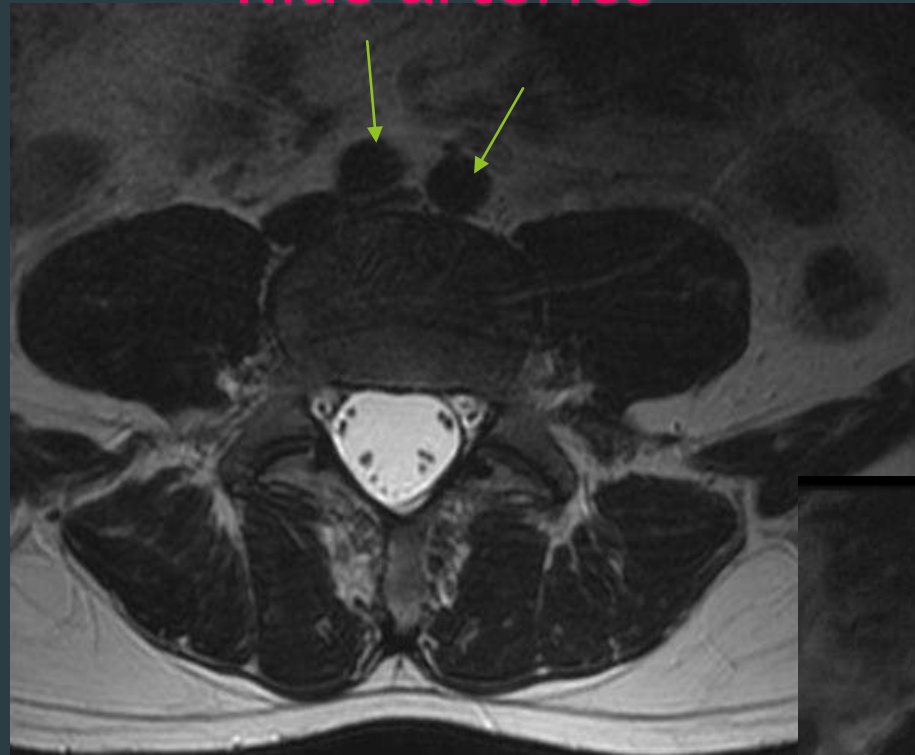
Anatomy on Axial Images

- Iliopsoas (orange), dorsal musculature (multifidus)



Anatomy on Axial Images

- ▶ Abdominal aorta- Level L3.
- ▶ Level of L4-L5: abdominal aorta bifurcates at the level of L4 into the right and left iliac arteries.



Note

- ▶ The multifidus muscle lies deep to the erector spinae muscles, where it fills the groove between the transverse and spinous processes of the vertebrae.

Nerve Roots in the Lumbar Spine- Two types

Exiting Nerve Roots

- ▶ The exiting nerve root exits 'below' in the lumbar spine. Example: At the L3-L4 disc level, the exiting nerve roots in the neural foramina are L3. At the L4-L5 disc level, the exiting nerve roots in the neural foramina are L4.
- ▶ At the L5-S1 disc level, the exiting nerve roots in the neural foramina are L5.

Descending Nerve Roots- Most commonly, cannot visualize the descending nerve roots at the disc levels of L1, L2 or L3, on the axial images. They tend to exit out of the thecal sac more inferiorly, in comparison to the L4 and L5 descending nerve roots.

- ▶ At the L4-L5 disc level, the descending nerve roots are L5.
- ▶ At the L5-S1 disc level, the descending nerve roots are S1.

- 

Figure # 9

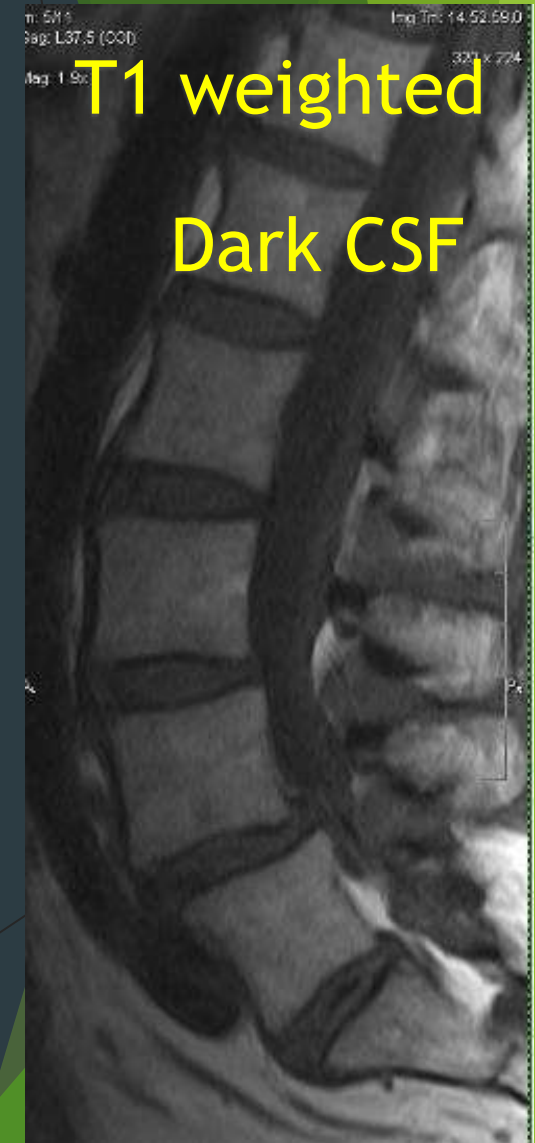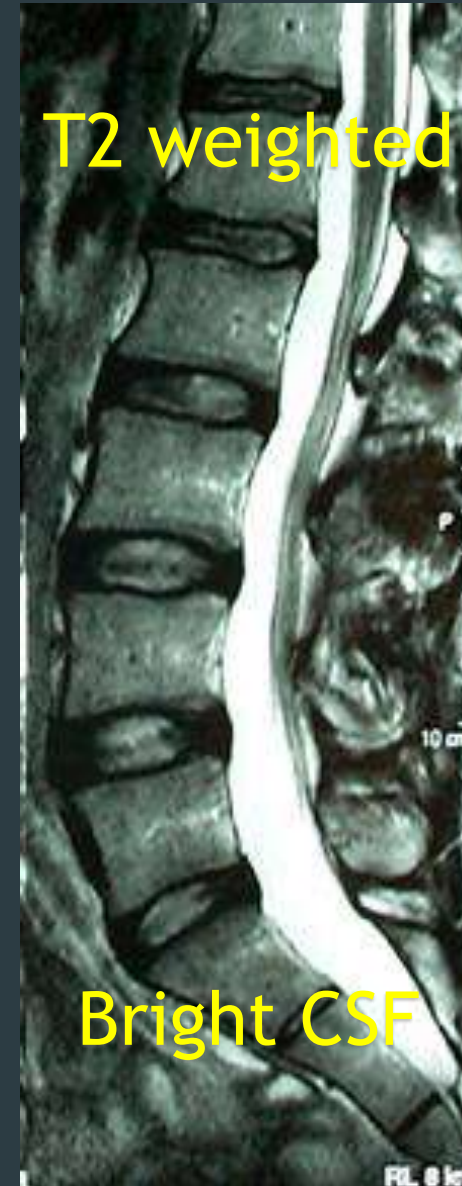


Types of MR Sequences

- ▶ You will never tell the MR technician or MR center what sequences to perform. Each scanner may have a different protocol.
- ▶ However, it is best to inform the imaging center that a stress fracture is a consideration or trauma has occurred. The imaging center will then perform a STIR (short tau inversion recovery) sequence.
 - ▶ Stress fractures and insufficiency fractures are best detected on STIR sequences.

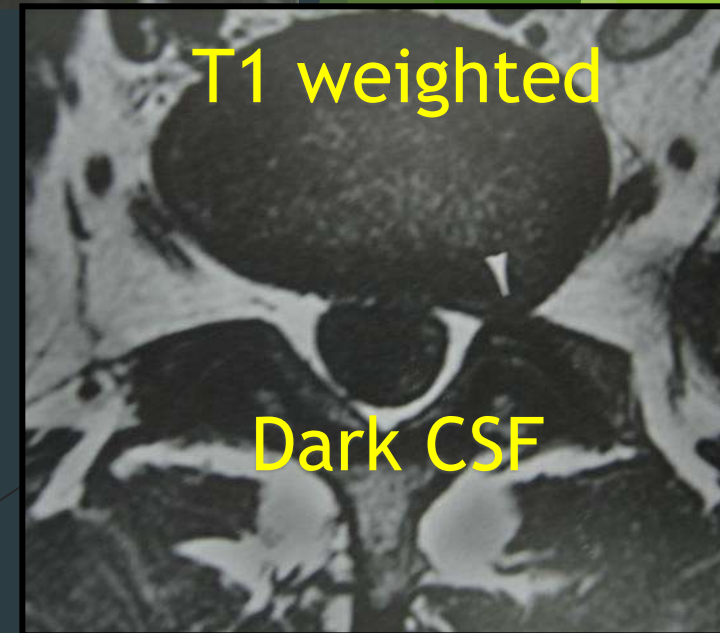
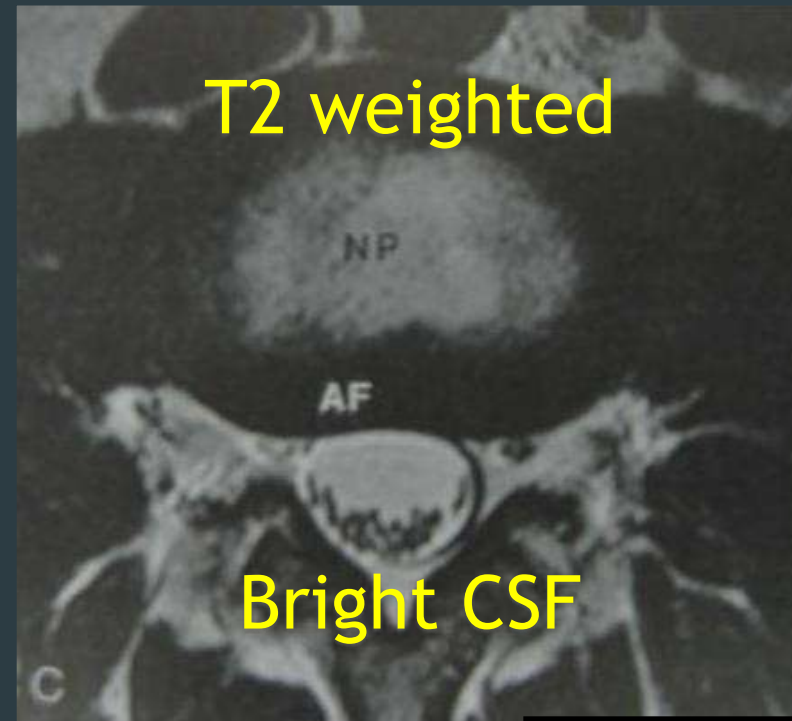
Types of MR Sequences

- ▶ T1 and T2 weighted images are the most common sequences performed for the spine.
- ▶ You don't need to know the physics of T1 or T2 😊 That's a different lecture!
- ▶ When evaluating the images, find the bright fluid signal of cerebrospinal fluid in the thecal sac....that would be the T2 weighted image. It is easy to find and easier to show your patient, in comparison to the T1 weighted images.



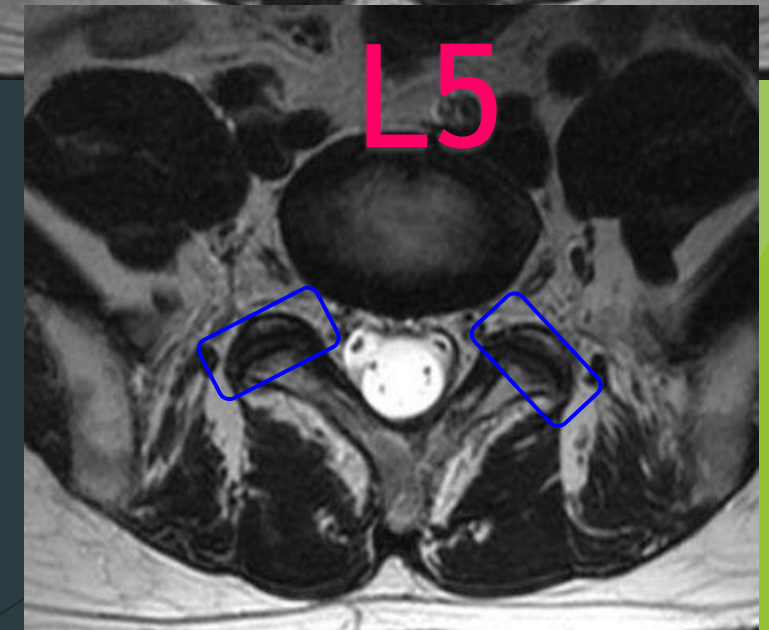
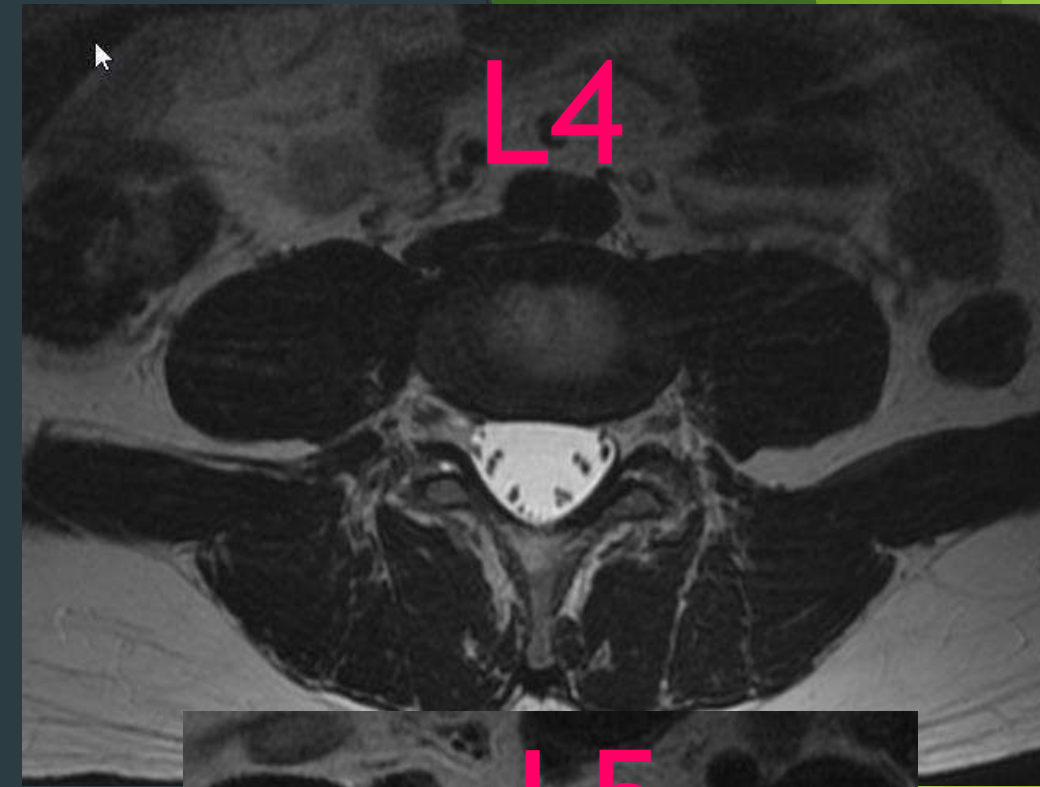
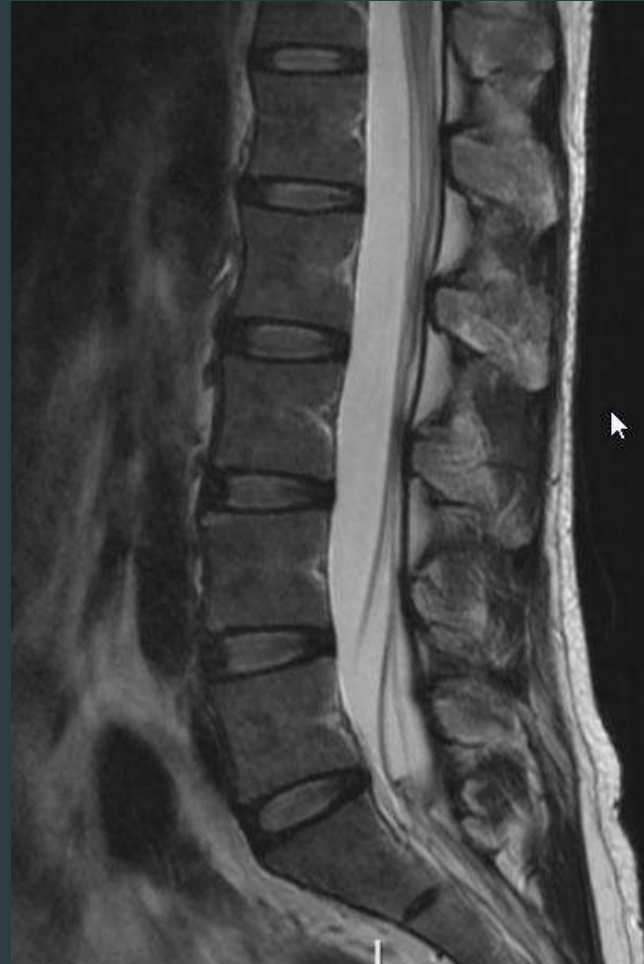Types of MR Sequences

- ▶ Axial image= Normal bright fluid content in the nucleus pulposus (NP)= T2 weighted image.
- ▶ Bright CSF= T2 weighted image
- ▶ Dark CSF= T1 weighted image



Normal Intervertebral Discs

- ▶ Normal disc spacing and normal disc signal intensity.
- ▶ Normal facet joints (blue rectangle)



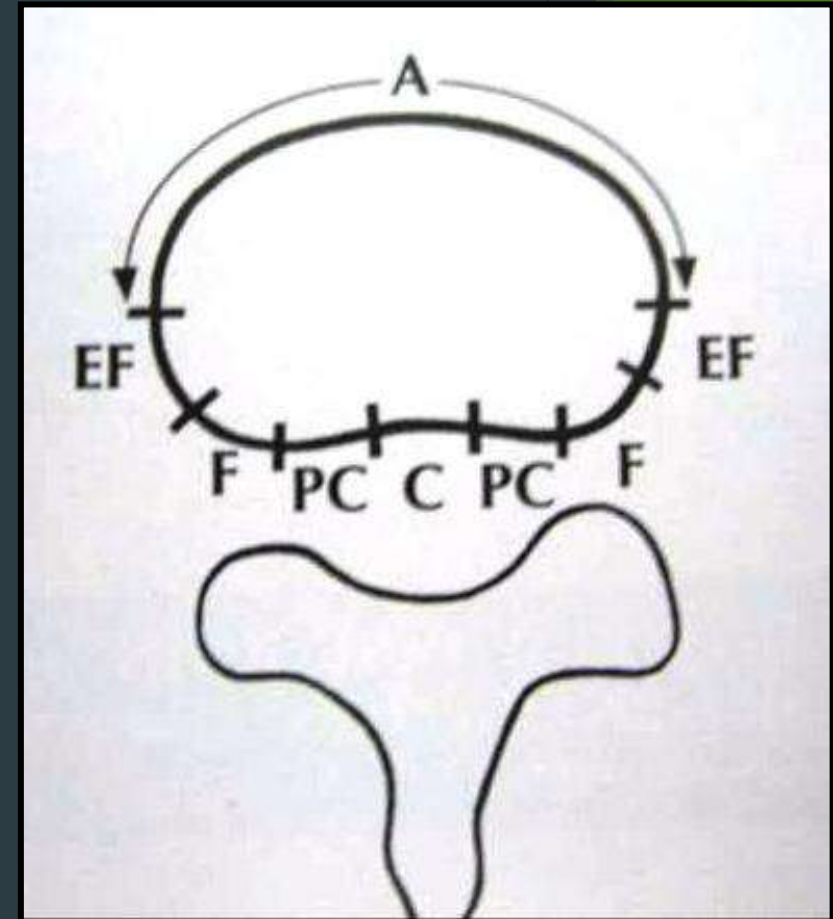
Nomenclature- Types of Posterior Disc Displacement

- ▶ Disc Bulge: Diffuse/Circumferential/Annular disc bulge----it all means the same.
- ▶ Disc Protrusion: Broad-based or Focal
- ▶ Disc Extrusion
- ▶ Sequestration

- ▶ Herniation: It is a generalized term for posterior disc displacement. Typically, it is used for protrusions, however, I have seen radiologists use it as a general term for any type of posterior displacement which is not helpful clinically.

Location of (Posterior) Disc Displacements

- ▶ Central
- ▶ Left/Right Central
 - ▶ Previous nomenclature was right and left paracentral (PC)
- ▶ Foraminal
- ▶ Extraforaminal
- ▶ Anterior



Further Grading

▶ Disc bulge, Protrusions and Extrusions

- ▶ Mild, moderate & severe grading terminology is subjective when evaluating the disc.
- ▶ Measurements of the disc are more objective and gives the clinician a visual of the size of the disc.

▶ **NOTE:** The measurement of the disc does **Not** depict surgery; surgery is based on decreased patient function, not the size of the disc bulge, protrusion or extrusion.

Further Grading

- ▶ Evaluating the neural elements: What is the posterior disc displacement doing to the nerve roots and thecal sac:
 - ▶ Encroachment,
 - ▶ Effacement or abutment, or
 - ▶ Compression (with displacement).

Evaluating Nerve roots and Thecal Sac

▶ Encroachment

- ▶ The best example is when someone is standing too close for comfort; or when someone is 'in-your-bubble'.
- ▶ The disc is near the nerve roots or thecal sac, but not touching it.

▶ Effacement or abutment

- ▶ The disc is ever so slightly touching the nerve roots and/or thecal sac, but not compressing or indenting the margins of the nerve root or thecal sac.

▶ Compression


- ▶ Indents the margins of the thecal sac and/or nerve roots, and could possibly displace these structures out of the normal position.

Disc Nomenclature

- ▶ Diffuse disc bulge
 - ▶ Asymmetrical disc bulge
- ▶ Broad-based protrusion
- ▶ Focal disc protrusion
- ▶ Disc extrusion
- ▶ Disc sequestration

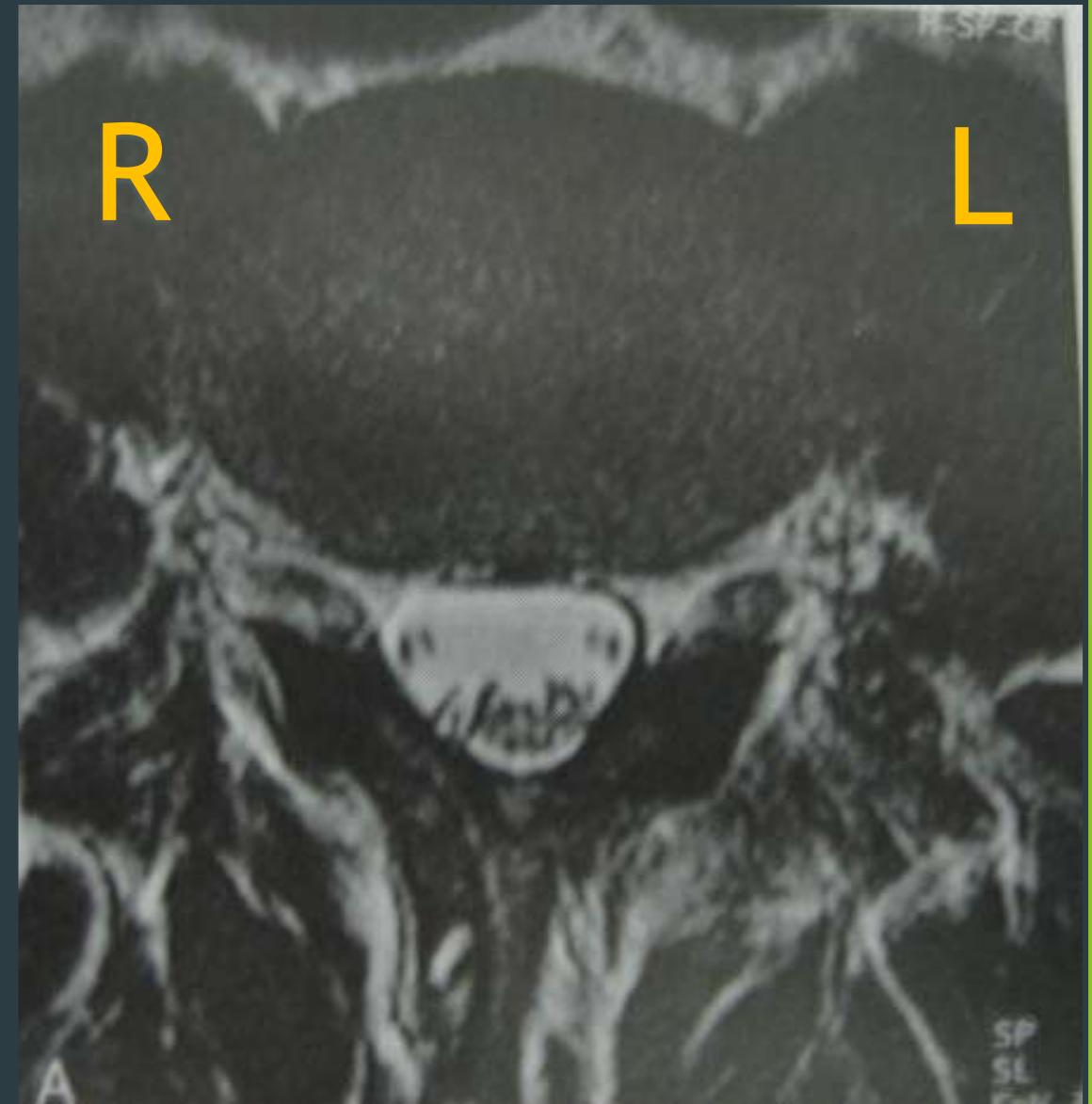
Diffuse Disc Bulge

- ▶ The margins of the disc surpass the entire circumference of the endplates.
- ▶ Also called a diffuse annular or circumferential disc bulge
- ▶ This can also be considered a “normal” finding in the aging spine; and cadaver studies have found bulging discs in asymptomatic patients as well.
- ▶ However, can bulging discs cause pain....Yes!



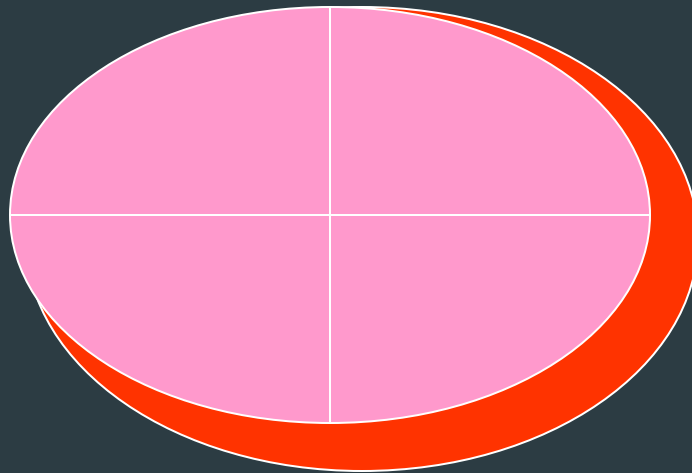
Diffuse Disc Bulge

- ▶ Axial, T2 weighted image of unknown level.
- ▶ CSF within the thecal sac is bright= T2 weighted image.



Asymmetrical Disc Bulge

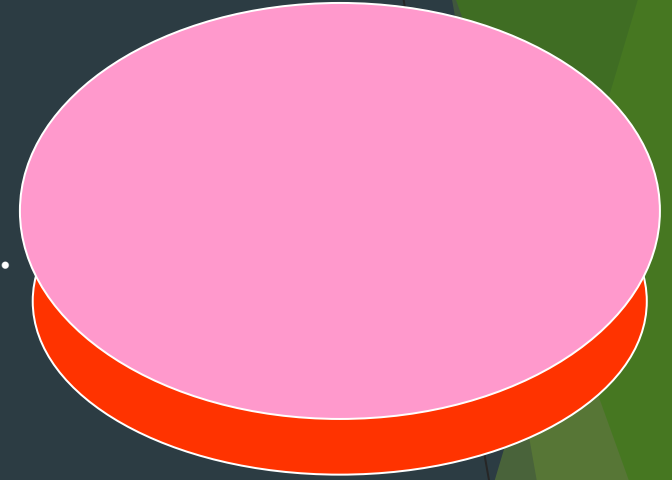
- ▶ Asymmetrical (or right/left lateral) disc bulge involving more than 50% of the disc circumference.
- ▶ Commonly seen with **scoliosis patients** due to the convexities.



Broad-based Protrusion & Focal Protrusion


Broad-based Disc Protrusion

- ▶ The disc is being displaced 25% to 50% of the disc circumference.
- ▶ Base of the disc protrusion is wider than the AP diameter.



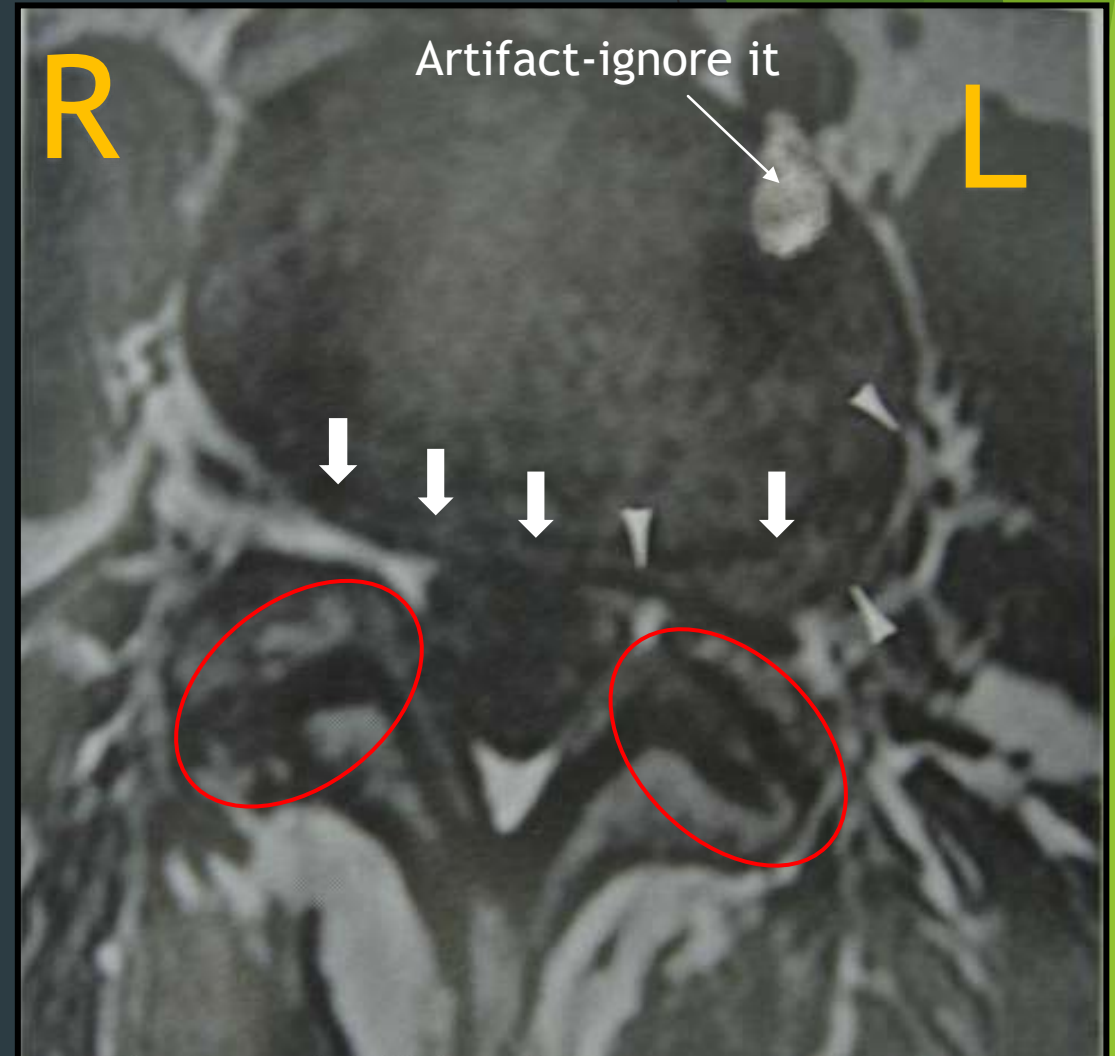
Focal Disc Protrusion

- ▶ The disc is being displaced 25% or less of the disc circumference.



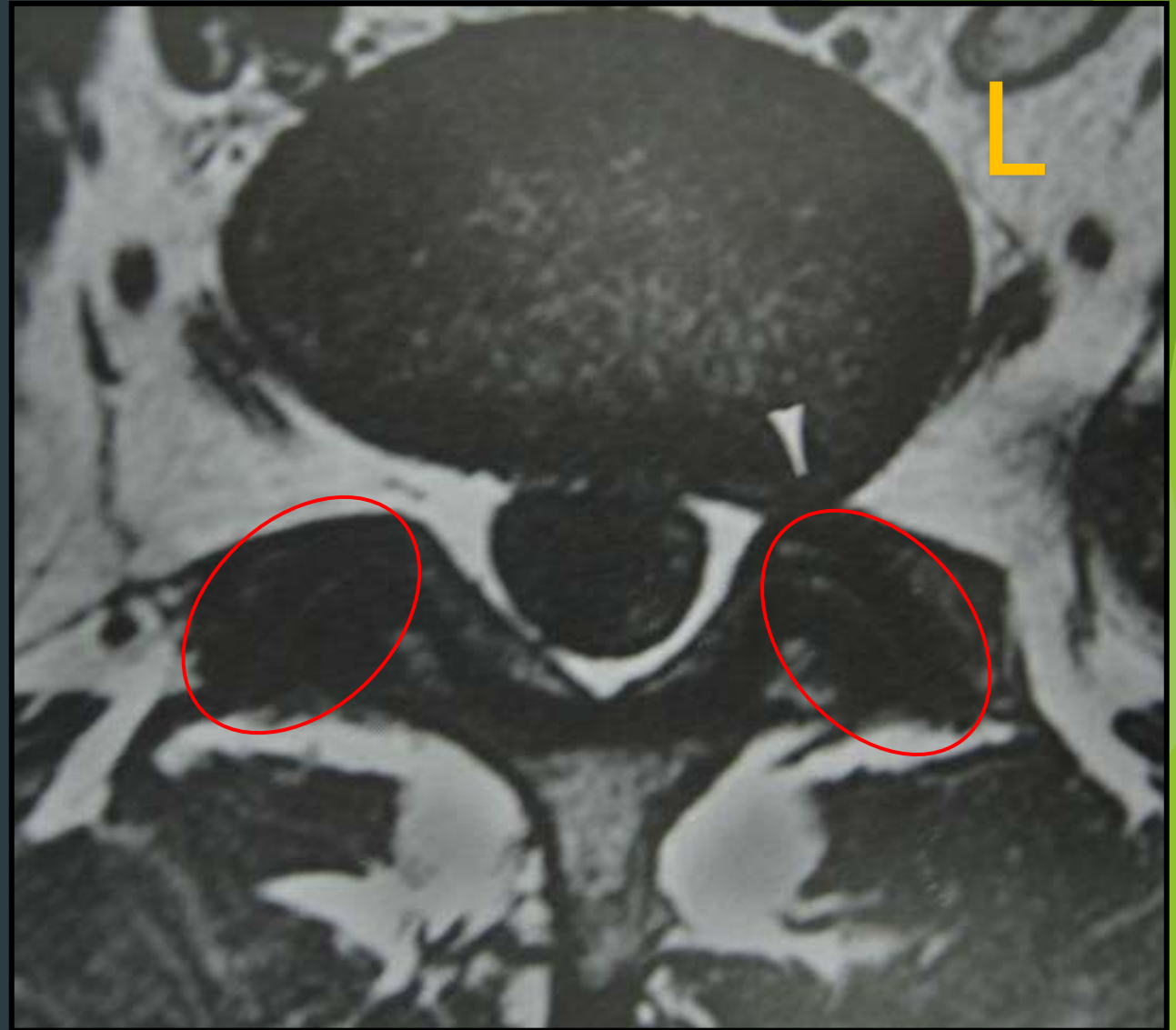Broad-based Disc Protrusion

- ▶ Axial, T1 weighted image of unknown level, CSF is dark on T1 weighted image.
- ▶ Broad-based left foraminal disc protrusion (white arrows).
- ▶ Need parasagittal images to comment on exiting nerve roots
- ▶ Facet joints (**red circle**) are normal.




Focal Disc Protrusion

- ▶ Axial, T1 weighted image of unknown level.
- ▶ Focal left foraminal disc protrusion.
- ▶ Need parasagittal images to comment on exiting nerve roots
- ▶ Facet joints (**red circle**) are normal.



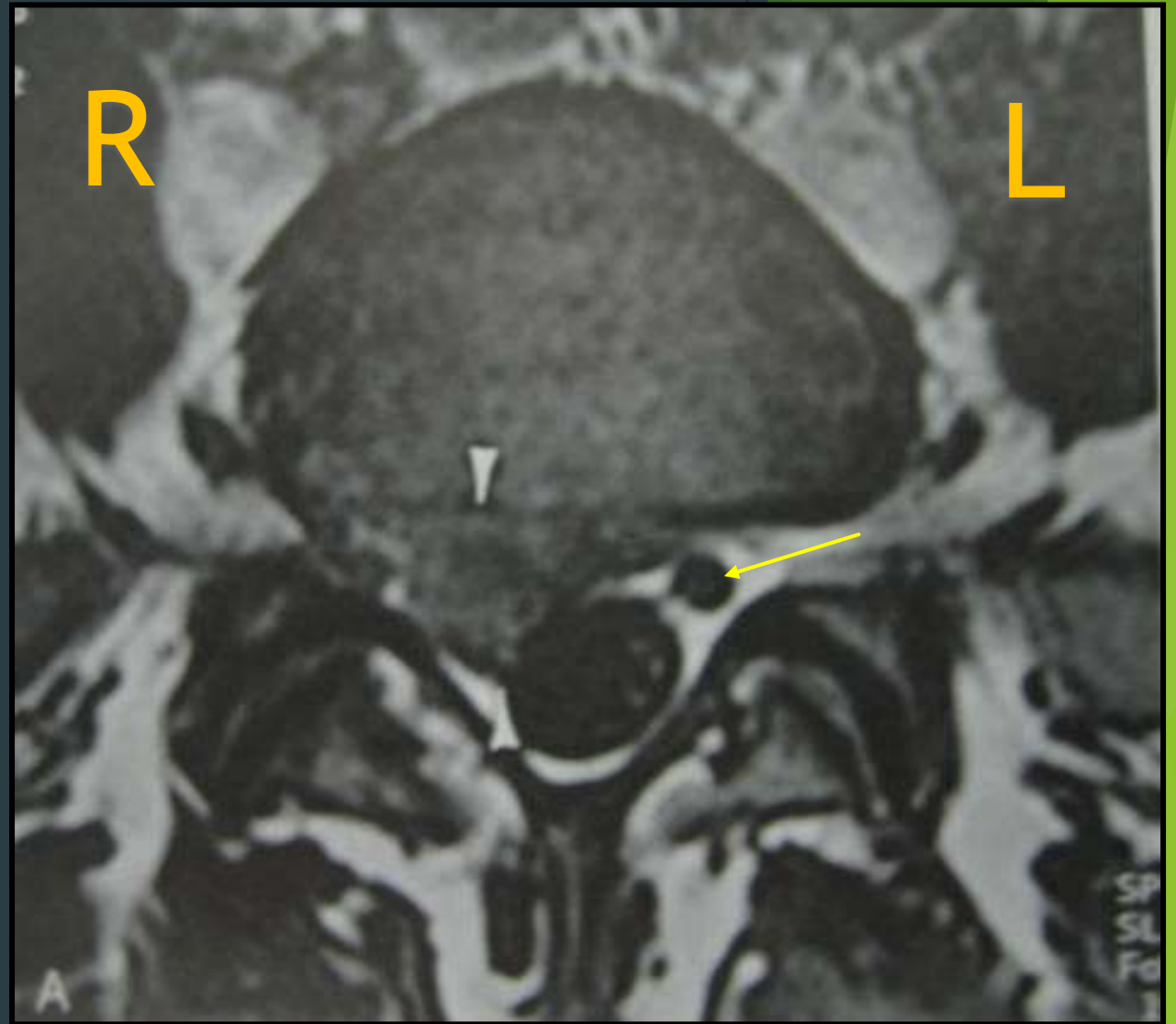
Disc Extrusion

- ▶ The disc is being displaced posteriorly at less than 25% of the disc circumference.
- ▶ The AP diameter is greater than the base, whereas, the protrusions have a wider base and does not extend posteriorly as much as an extrusion.
- ▶ Maintains contact with parent disc



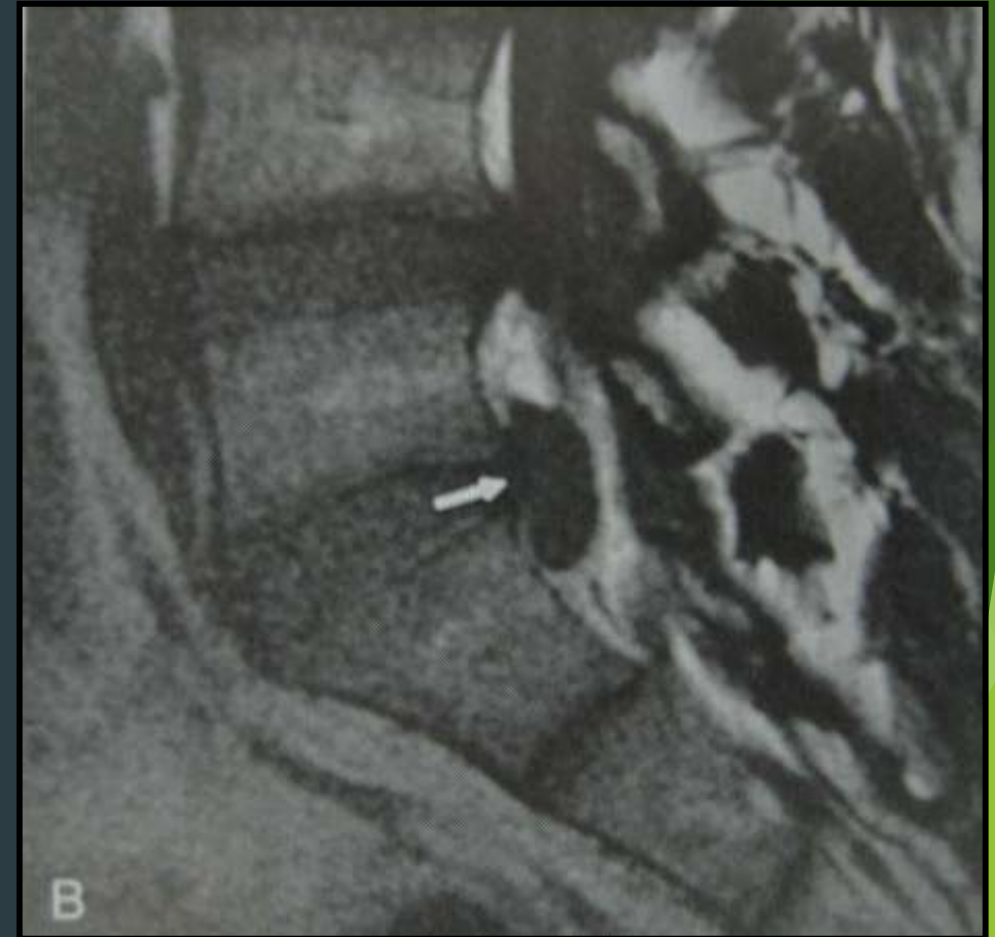
Disc Extrusion

- ▶ Axial image of L4-L5.
- ▶ L4-L5: Right central disc extrusion is compressing the thecal sac and right L5 descending nerve root.
- ▶ There is also encroachment to the left L5 descending nerve root (**yellow arrow**).




Disc Extrusion

- ▶ Sagittal image
- ▶ L5-S1: Disc extrusion with cephalad and caudal migration is compressing the thecal sac with severe spinal canal stenosis.
- ▶ Suspected disc protrusion at L4-L5.



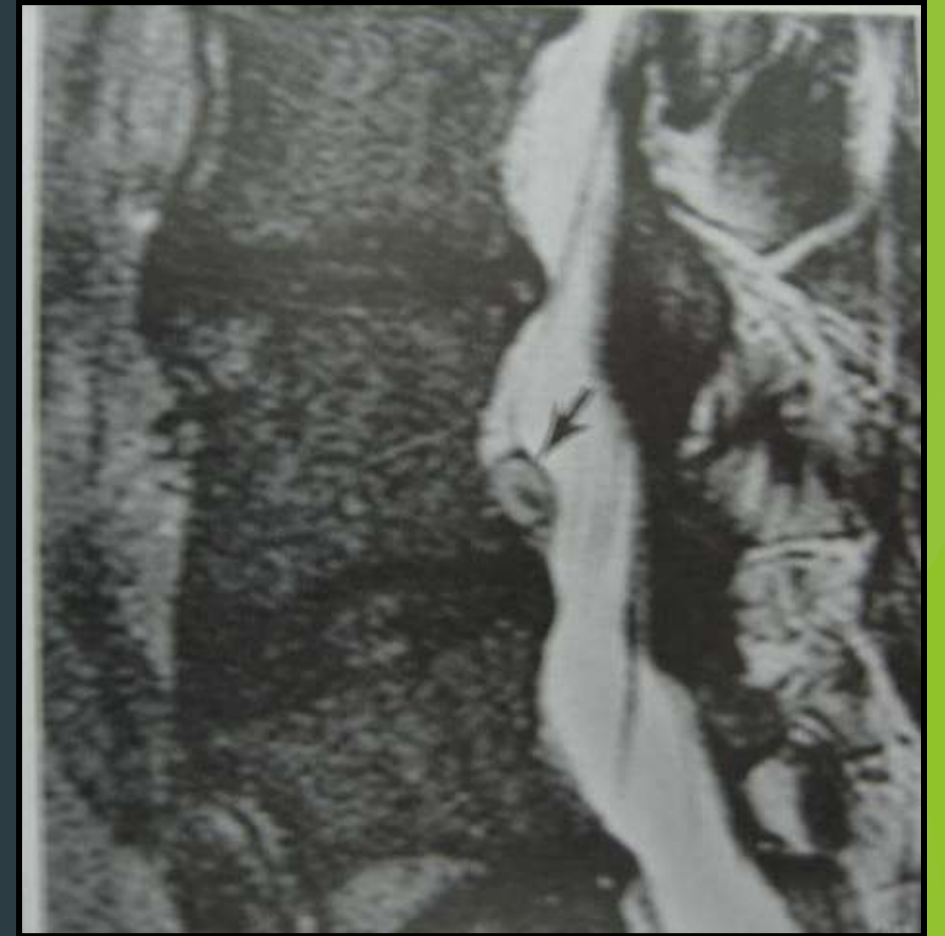Disc Sequestration

- ▶ Loss of continuity to the parent disc; Free fragment—might be a better term.



Disc Sequestration

- ▶ Sagittal image
- ▶ Arrow is pointing to a sequestration, where a piece of disc material broke off from the parent disc (in this pic, not sure where it came from).
- ▶ The signal is bright within the fragment due to inflammatory properties.

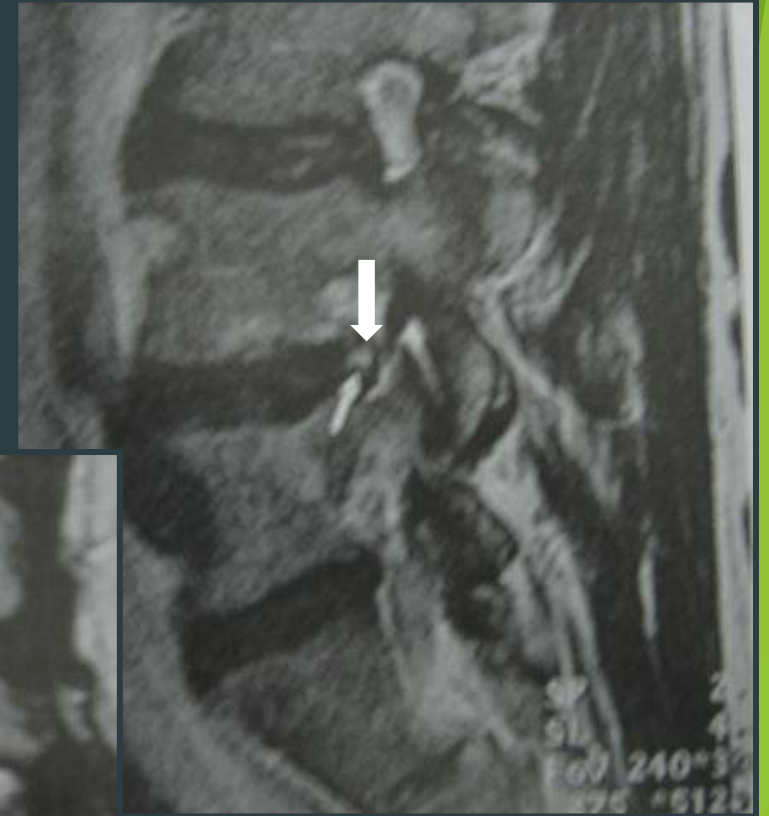
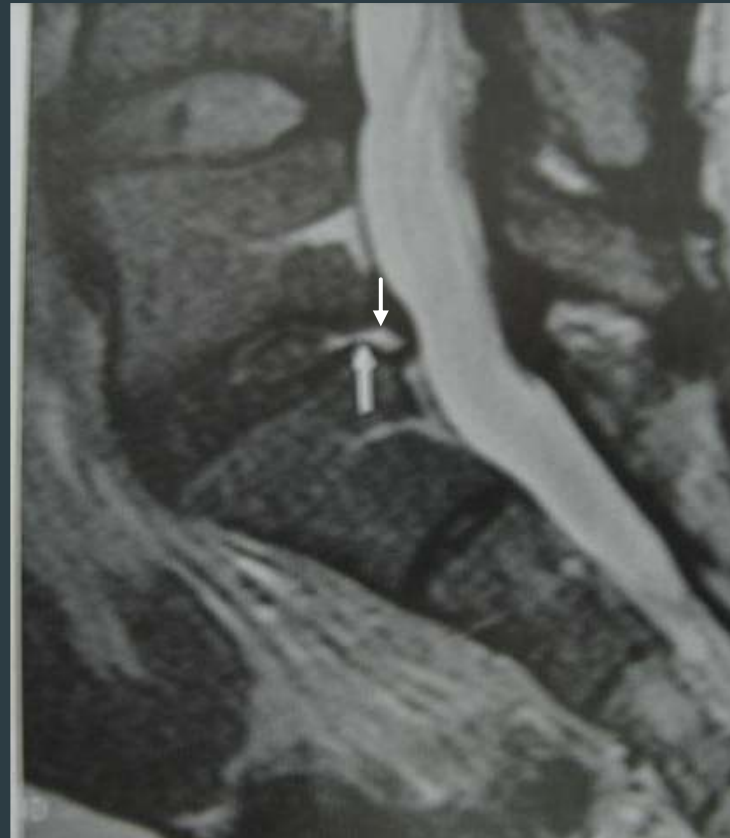
Other Items: Annular Fissure/Defect/Tear

- ▶ Aka High Intensity Zones
 - ▶ Typically, shown as a small globular bright white signal on the T2 and STIR weighted images within the **annulus fibrosus**.
 - ▶ **Pain generators** particularly when located in the posterior aspect of the disc, a highly innervated region of the disc.

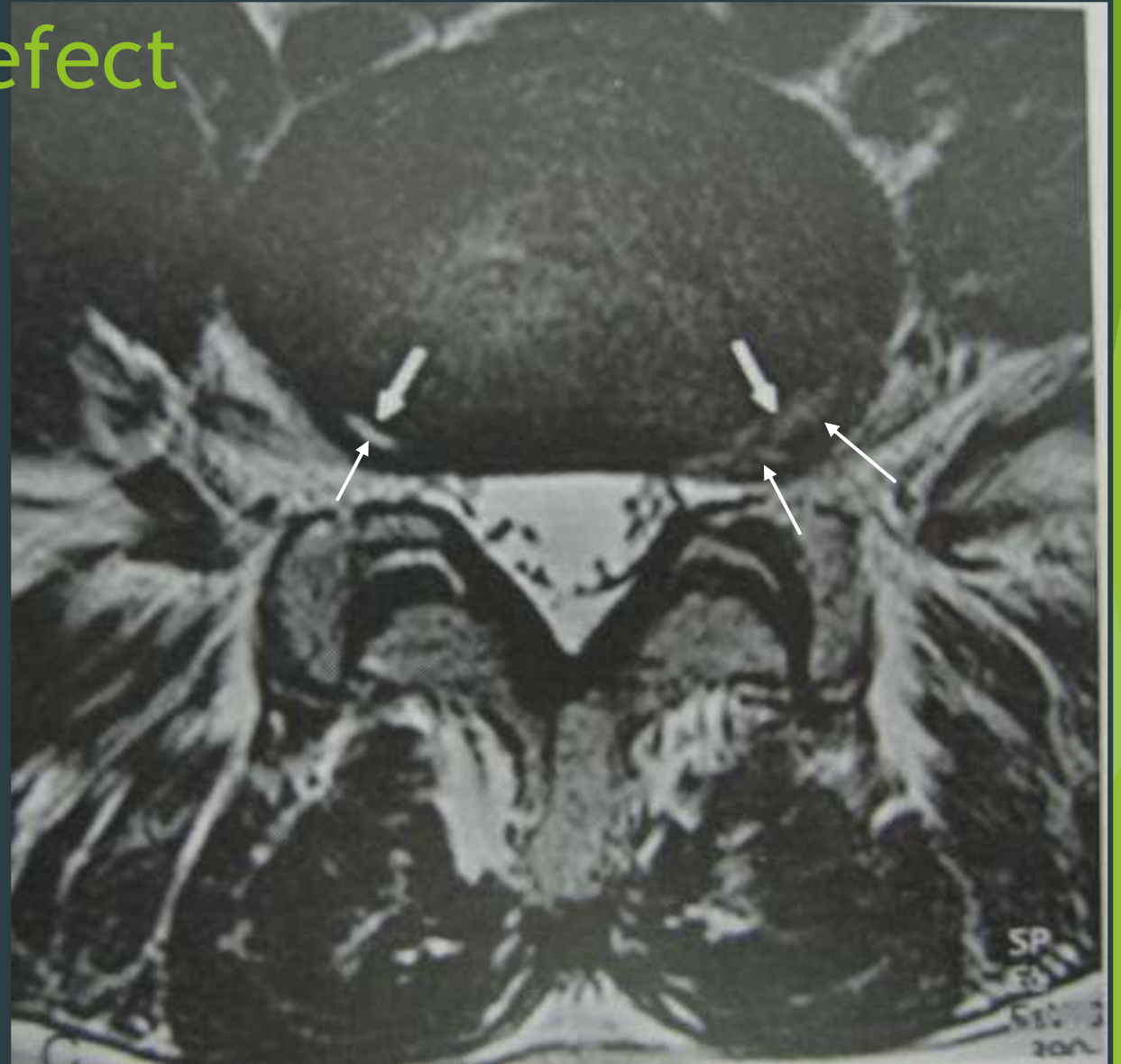
Annular Fissure/Tear/Defect

- ▶ Linear or globular high signal intensity within the annulus fibrosus.
- ▶ These are detected on the T2 and STIR weighted images.



Annular Fissure/Tear/Defect

- ▶ Axial T2 weighted image:
Linear/globular high signal intensity within the annulus fibrosus.
- ▶ Focal right and left foraminal disc protrusions with superimposed diffuse disc bulge are compressing the thecal sac, resulting in mild spinal canal stenosis.



Keep in Mind When Viewing Cases

- ▶ What type of disc are we looking at relative to the sagittal and axial images?
- ▶ Where is the disc going? (Location-central, right/left central, foraminal)
- ▶ What is the disc doing to the thecal sac? (Encroachment, Effacement, Compression)
- ▶ What is the disc doing to the descending and exiting nerve roots?
- ▶ Is the disc and/or bony structures resulting in **spinal canal or neural foramina stenosis**? If so, how much?
 - ▶ **We can grade spinal canal and neural foramina stenosis by using mild, moderate or severe.**
 - ▶ When writing reports, the terms mild, moderate or severe (subjective) are **NOT** used when describing a disc. It would be ideal to give **measurements** (more objective) of the disc bulge/protrusion/extrusion.

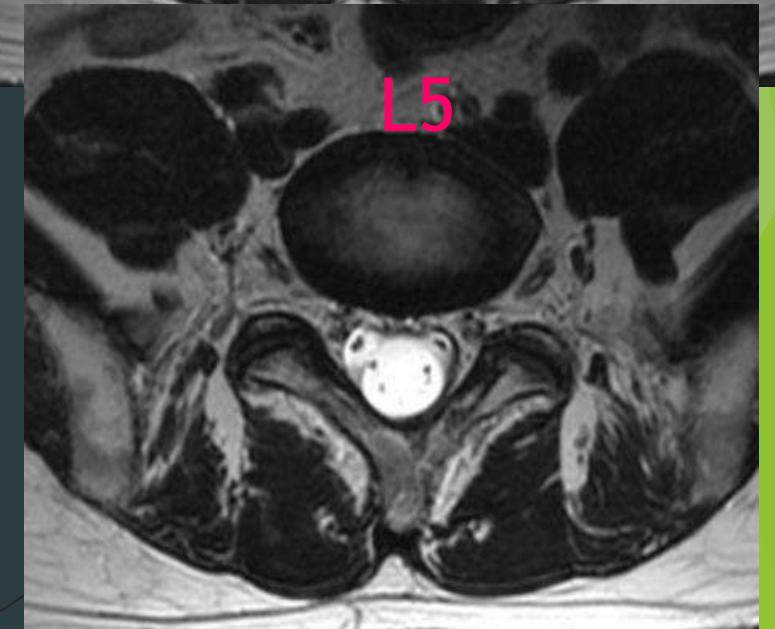
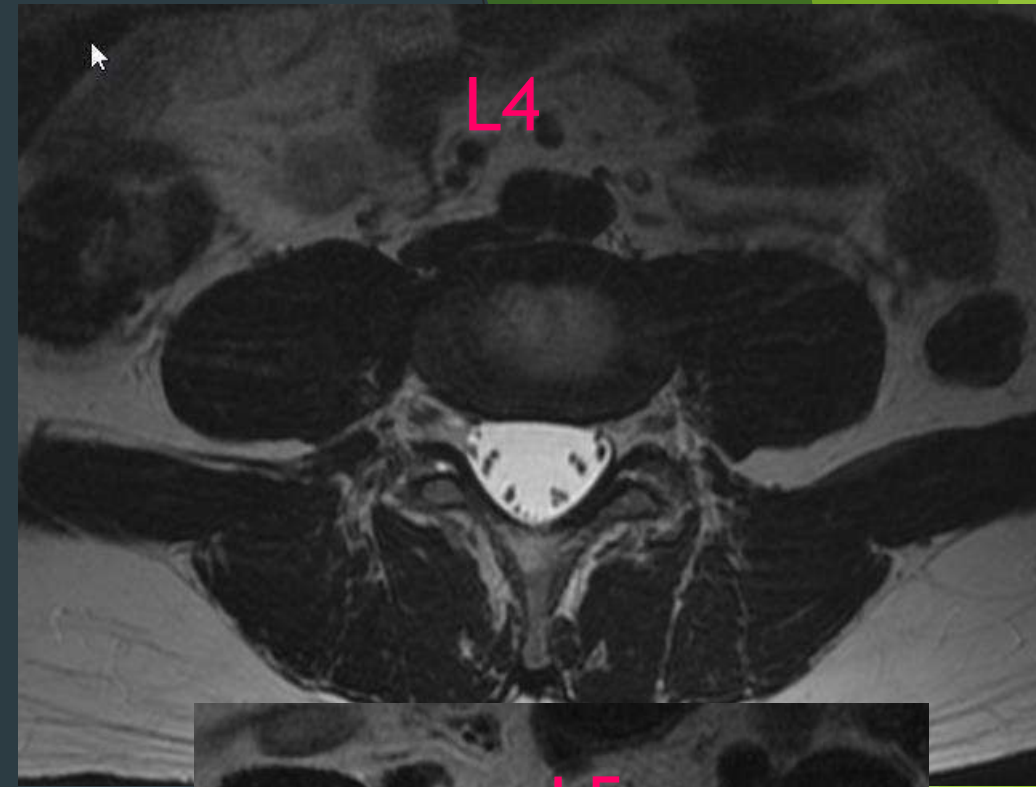
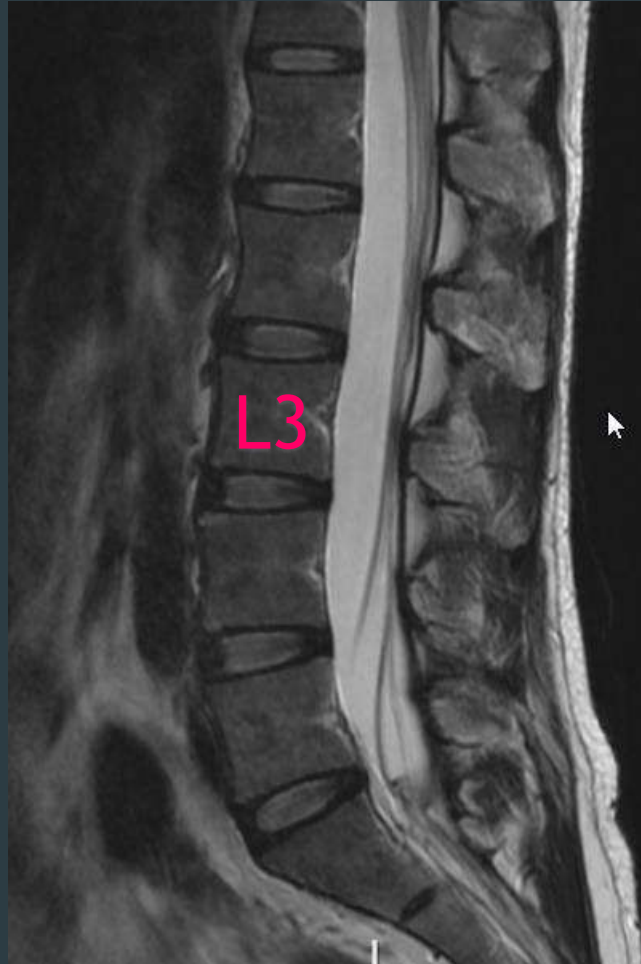Case Studies---Now we can test your knowledge😊

- ▶ Putting it together
- ▶ Some cases will have xrays, followed by MRI.
- ▶ And sometimes, there is no specific history beside Low Back Pain....welcome to my world😊

Starter: Examples of Normal versus Abnormal Discs

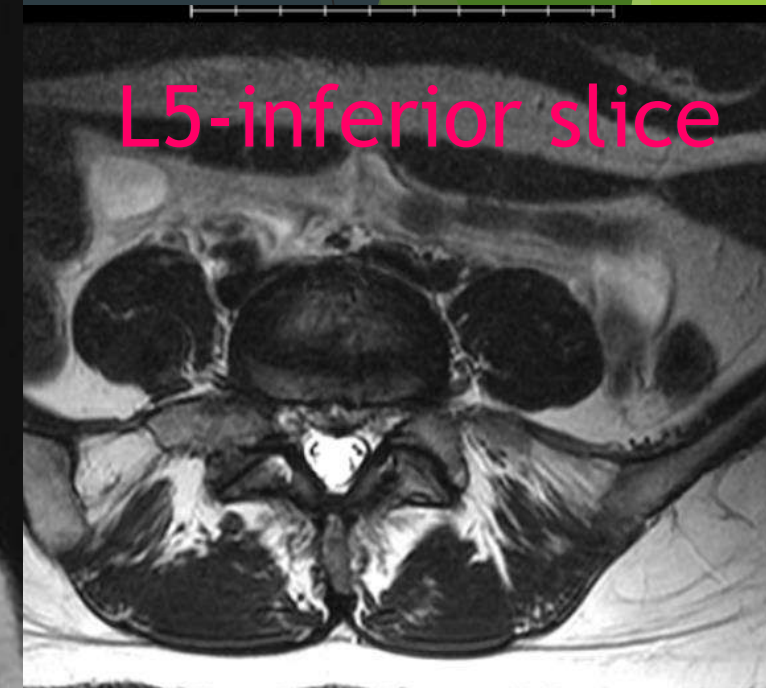
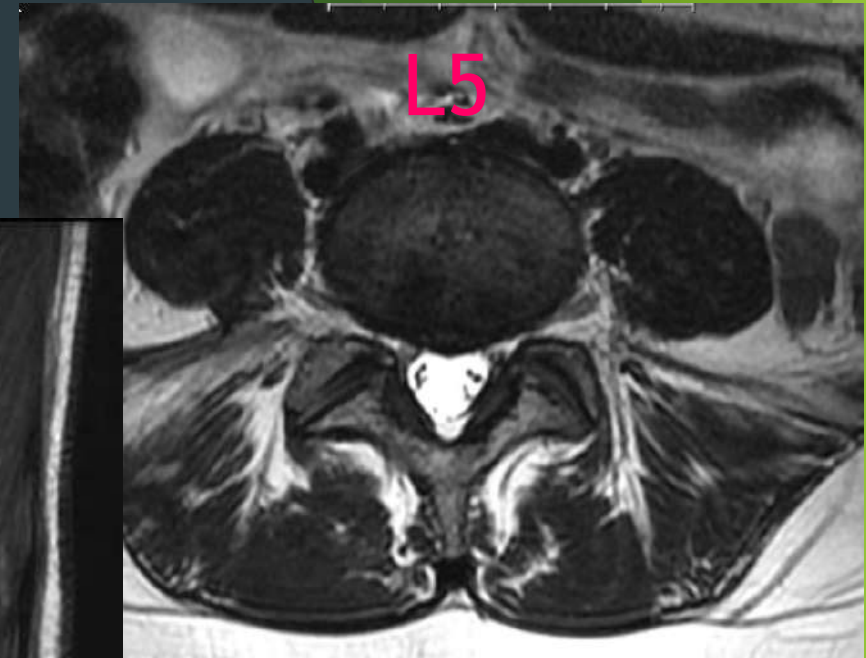
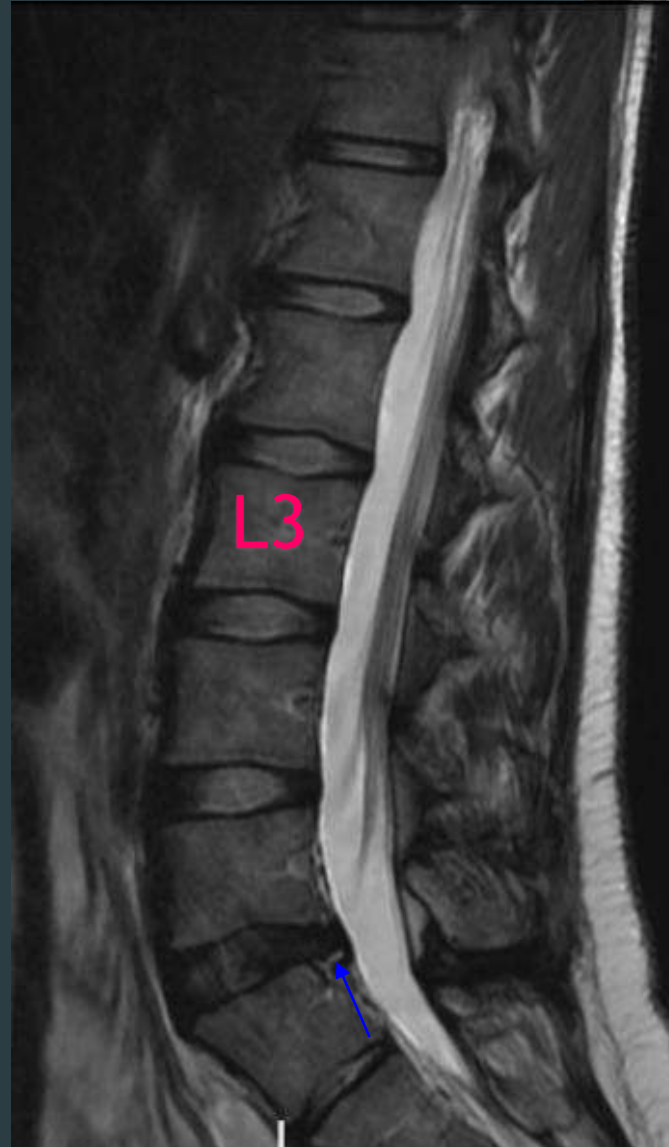Normal Intervertebral Discs

- ▶ Normal disc spacing and signal intensity.
- ▶ Top is L4 axial; Bottom is L5 axial
- ▶ Normal facet joints



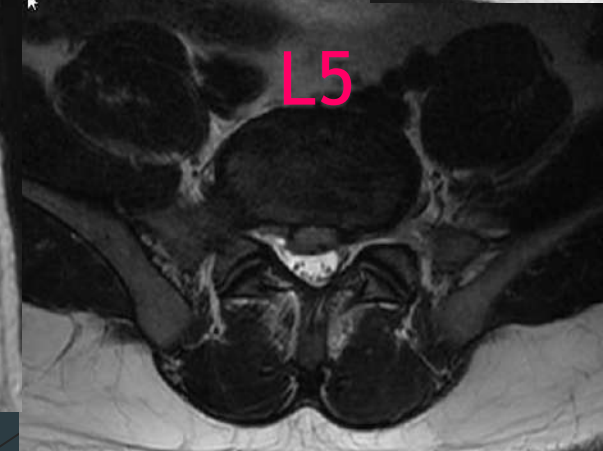
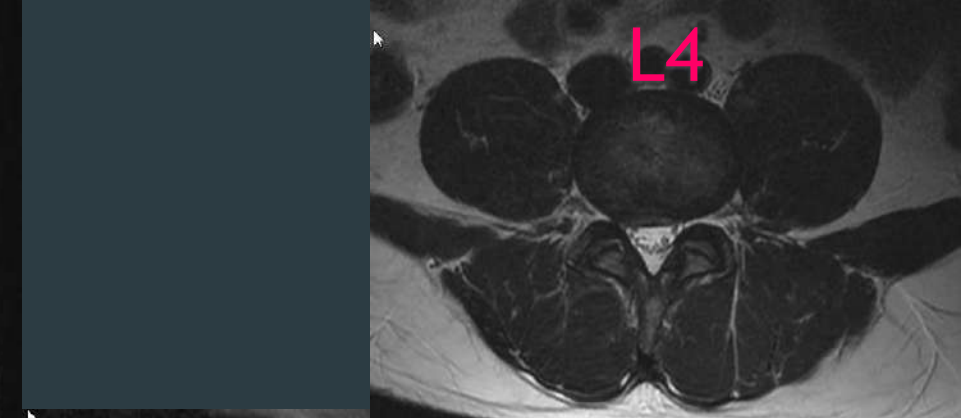
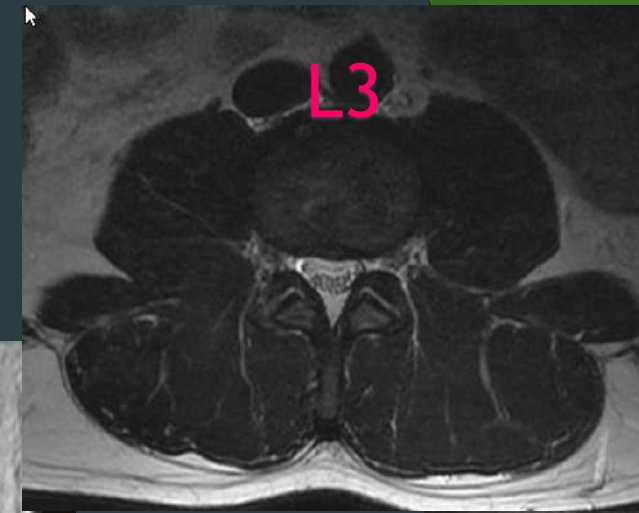
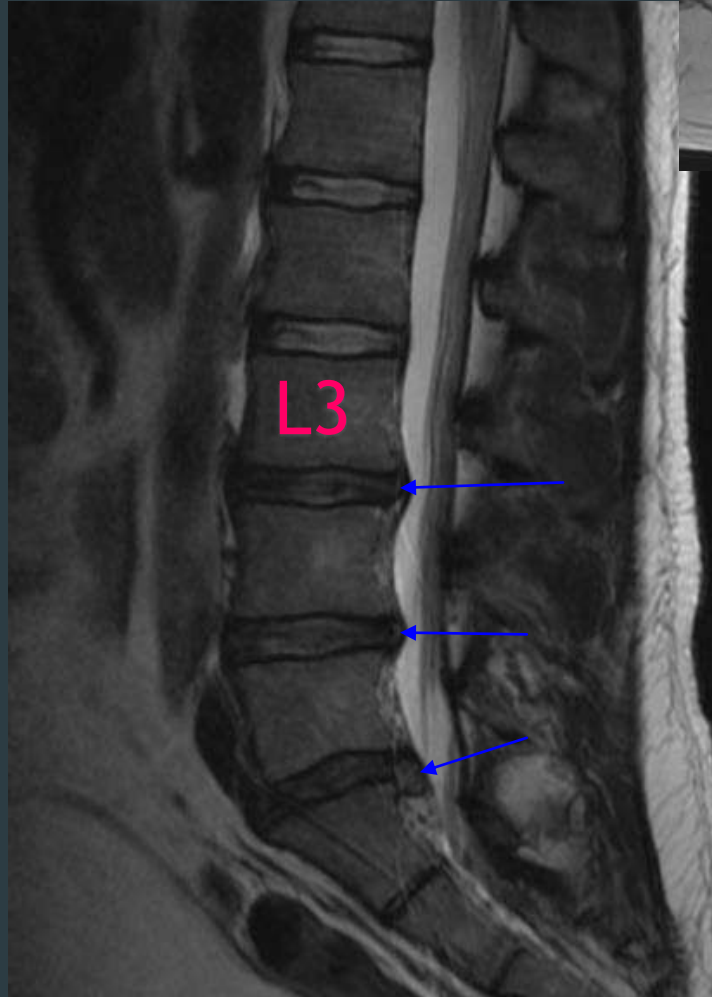
Abnormal disc at L5-S1

- ▶ L5-S1: Central disc extrusion with inferior migration is compressing bilateral S1 descending nerve roots; Disc desiccation/dehydration.
- ▶ Annular fissure/tear/defect (blue arrow).
- ▶ Normal discs from T12 to L4.



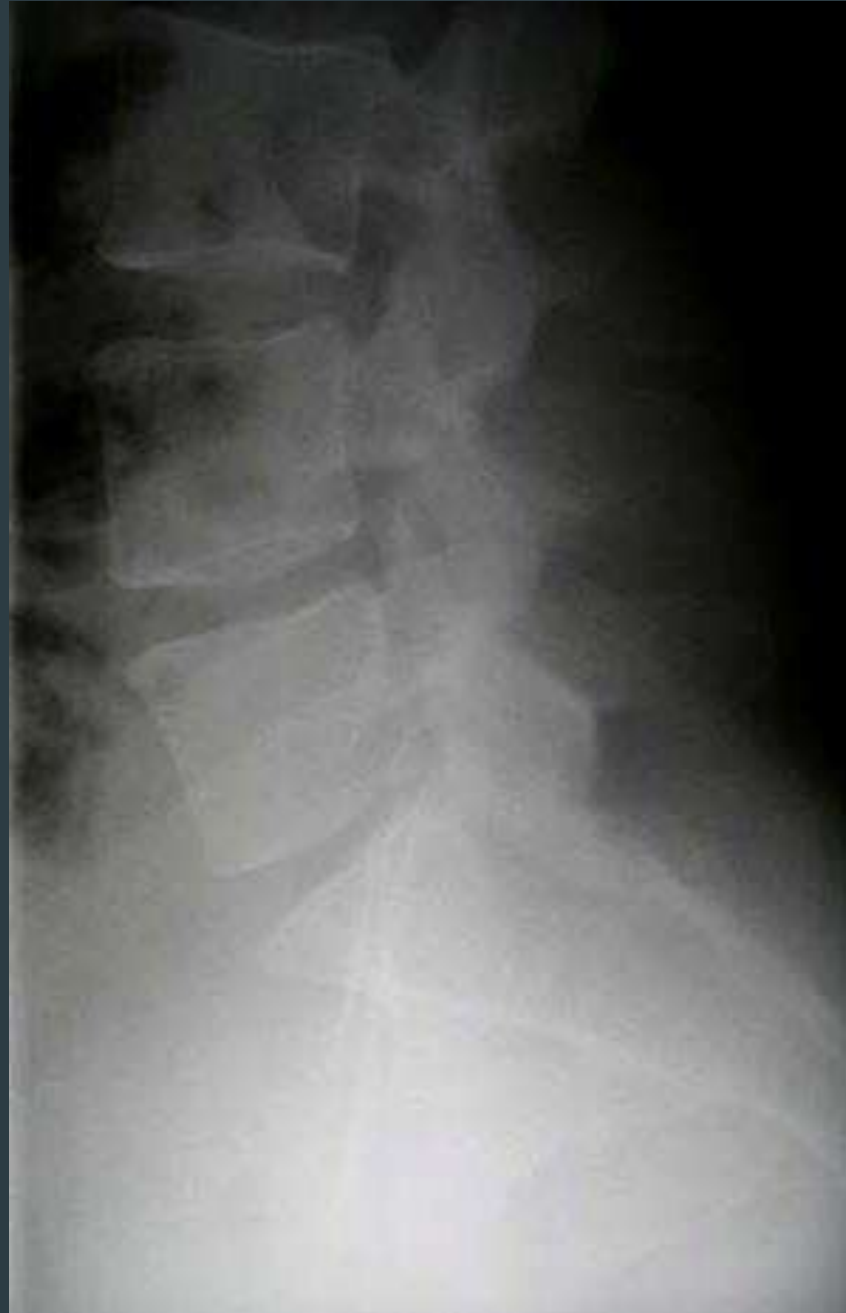Examples of Abnormal discs

- ▶ Disc desiccation and disc narrowing at L3, L4 & L5.
- ▶ L3-L4: Diffuse disc bulge
- ▶ L4-L5: Right central focal disc protrusion; Annular fissure/tear/defect
- ▶ L5-S1: Central disc extrusion; Annular fissure/tear/defect
- ▶ T12, L1 and L2 discs are normal.



Case 1

www.spineuniverse.com



Diagnosis for Lateral Lumbosacral spot

- ▶ Mild disc space narrowing at L4-L5 and L5-S1.
- ▶ Degenerative retrolisthesis at L5 of 1.7 mm.
- ▶ Mild facet arthrosis at L4-L5 and L5-S1.
- ▶ Osseous neural foramina stenosis at L4-L5 and L5-S1 due to the forementioned degenerative changes.

Lateral Lumbosacral spot

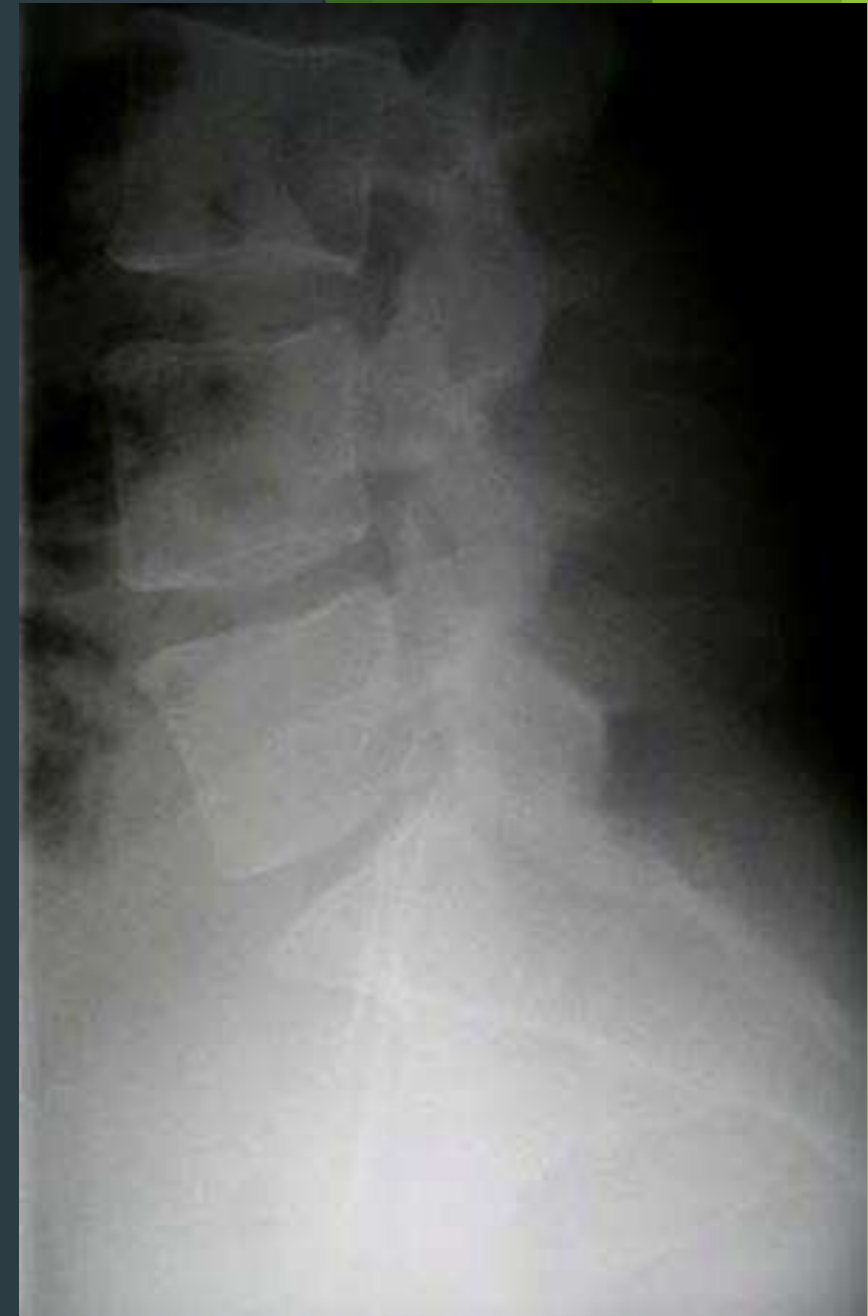- ▶ Follow-up imaging

- ▶ MRI....why?

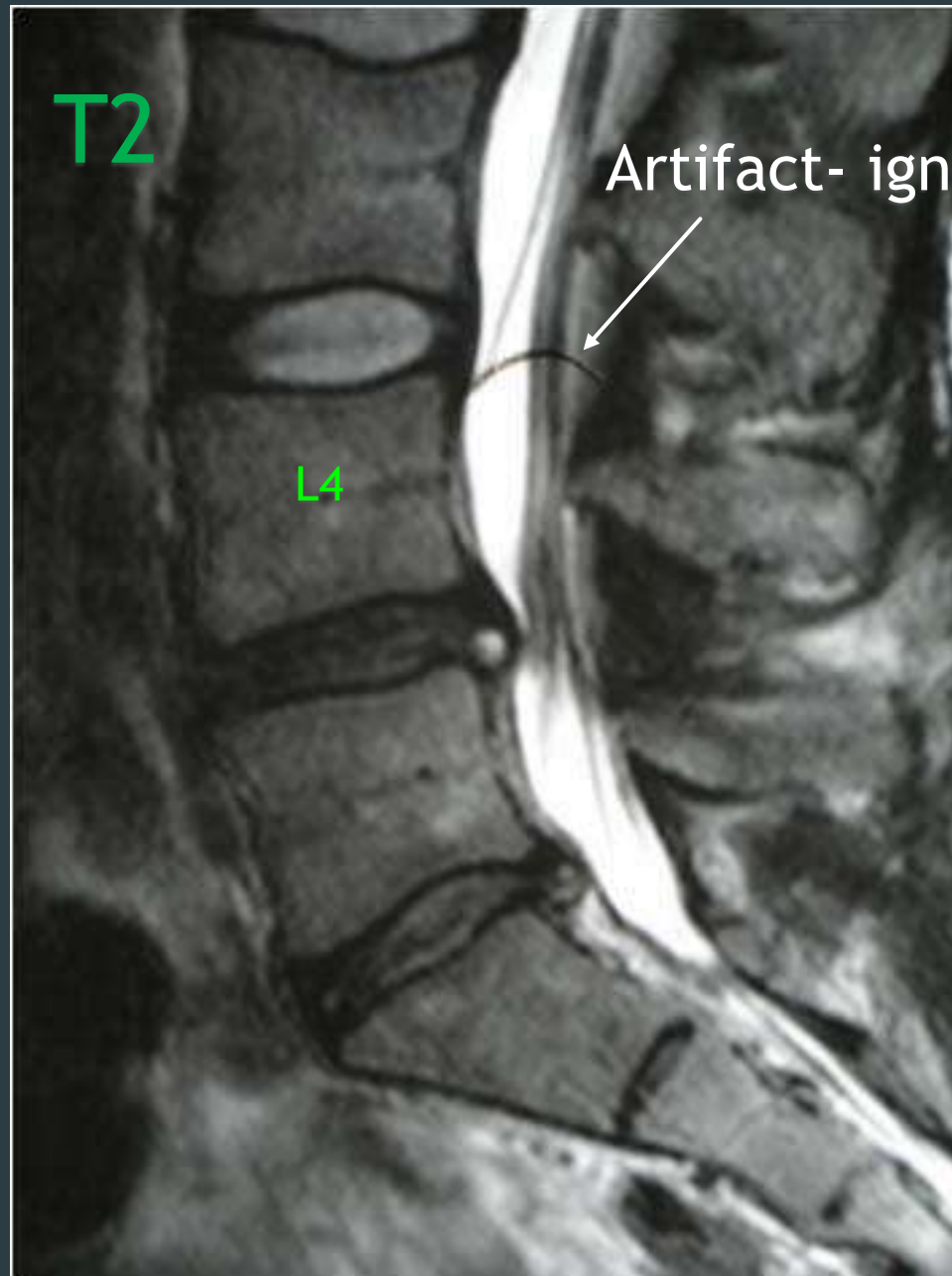- ▶ Degenerative changes, osseous neural foramina stenosis, symptoms/function of the patient, not responding to conservative treatment.

- ▶ The next step is MRI without contrast.

- ▶ Note: Conservative treatment is considered as physical therapy, acupuncture, chiropractic, massage therapy, etc.

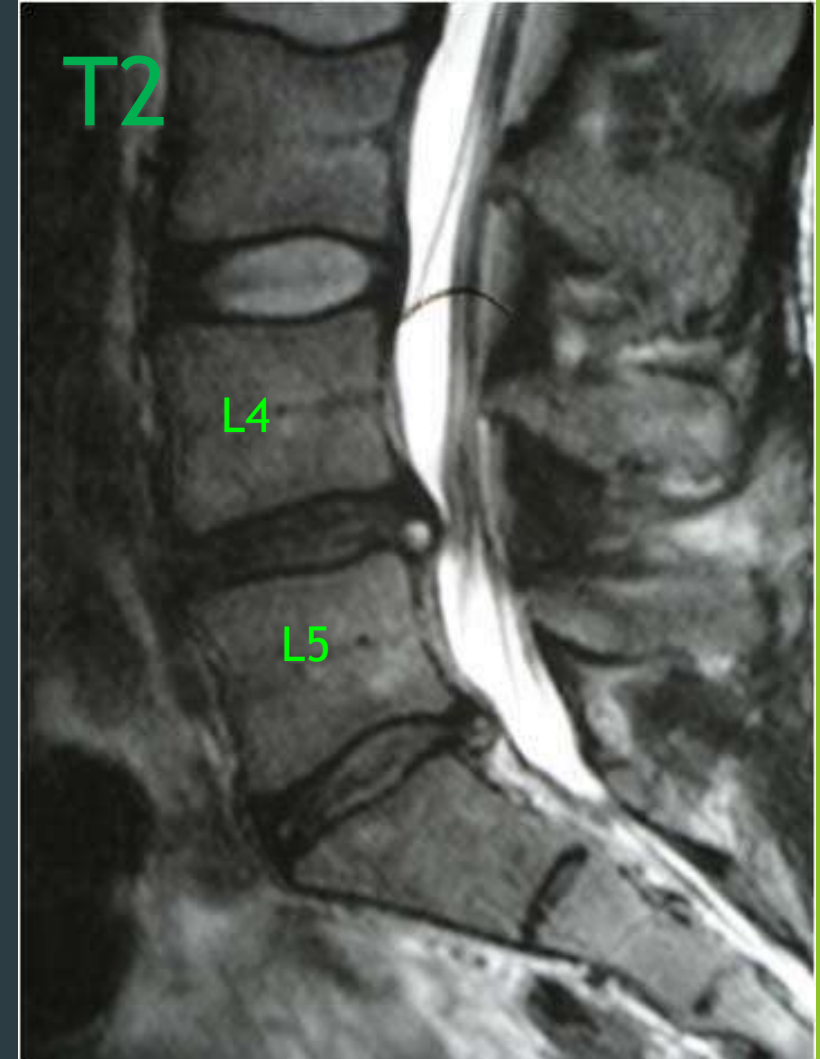

Sagittal T2 is magnified



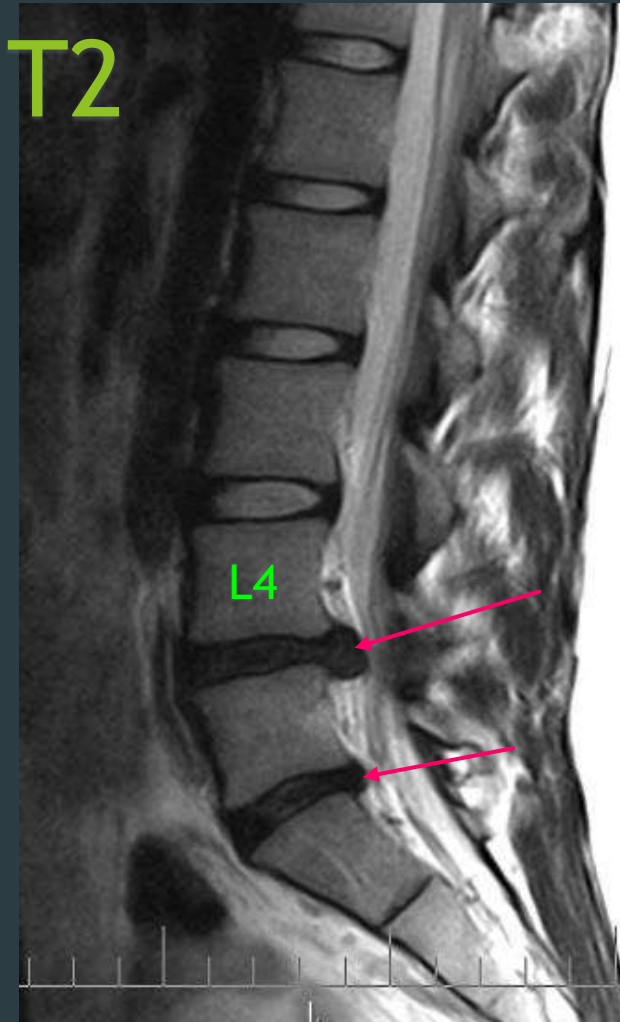
Diagnosis

- ▶ L4-L5: Disc protrusion is compressing the thecal sac with mild spinal canal stenosis.
 - ▶ Annular fissure/tear/defect, and disc desiccation/dehydration and disc narrowing
- ▶ L5-S1: Disc protrusion is compressing the thecal sac with mild spinal canal stenosis.
 - ▶ Annular fissure/tear/defect and disc desiccation and narrowing.
- ▶ Mild posterior spondylosis at L5-S1.
- ▶ We need the axial images to evaluate if the protrusion is central, right/left central, etc.

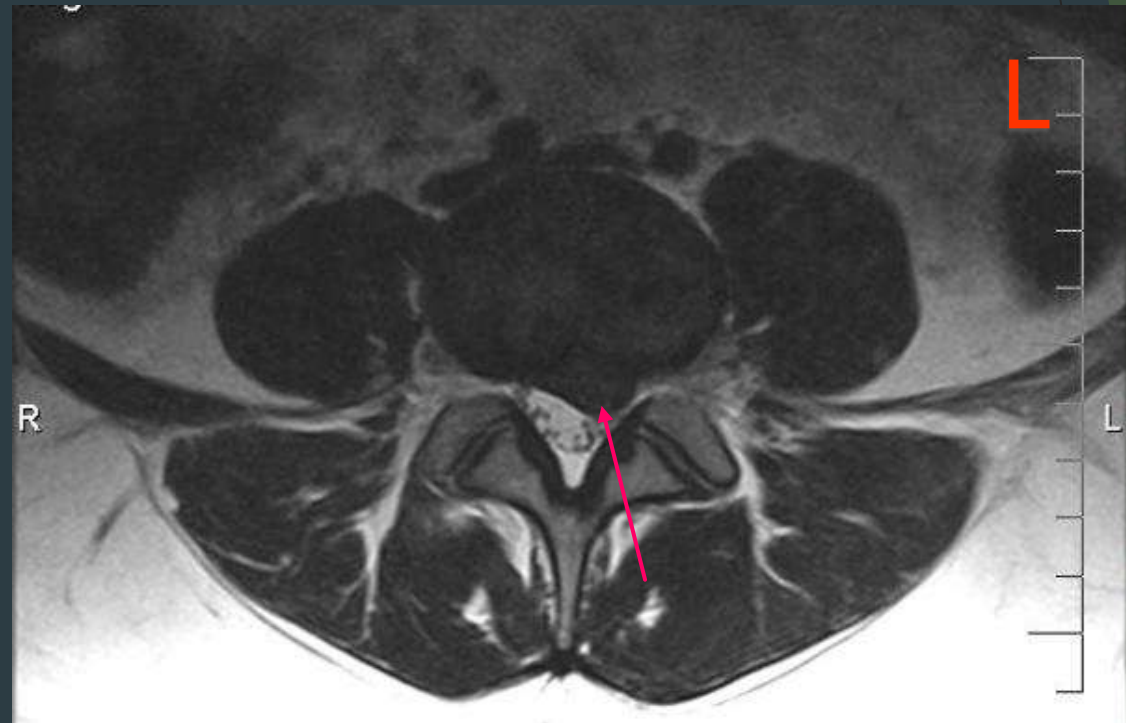


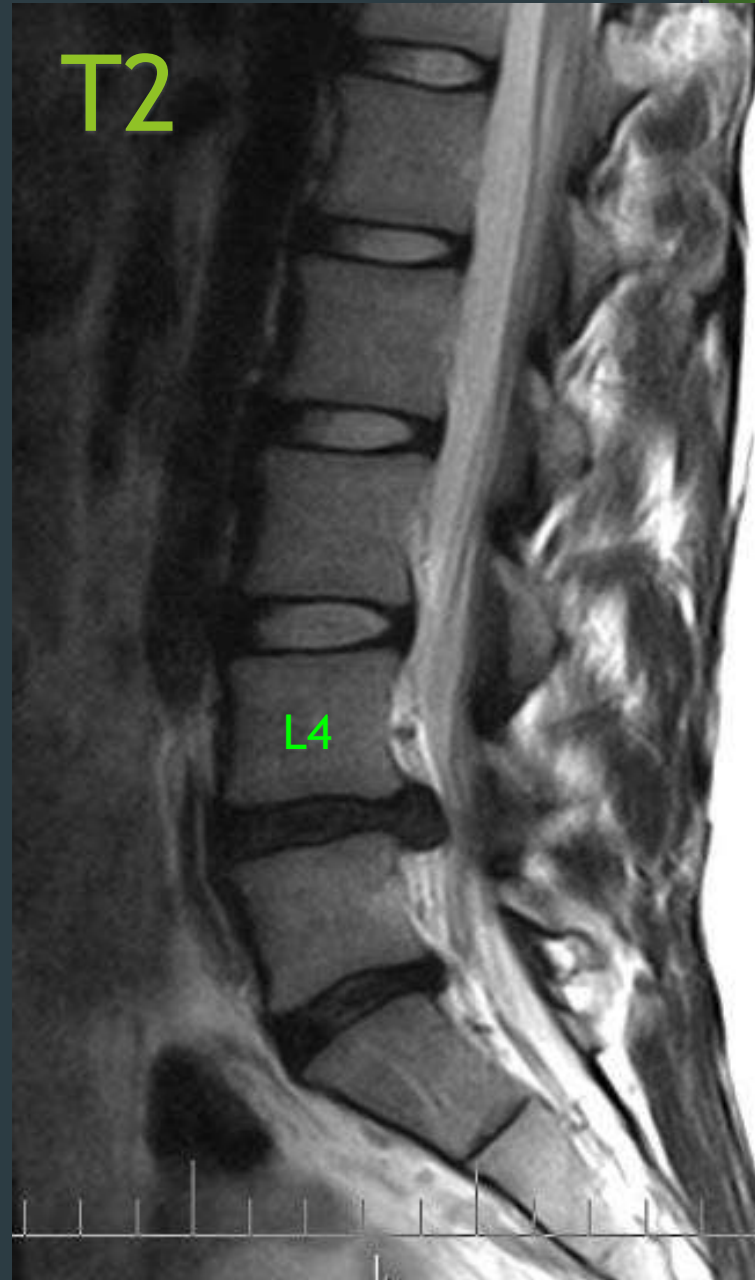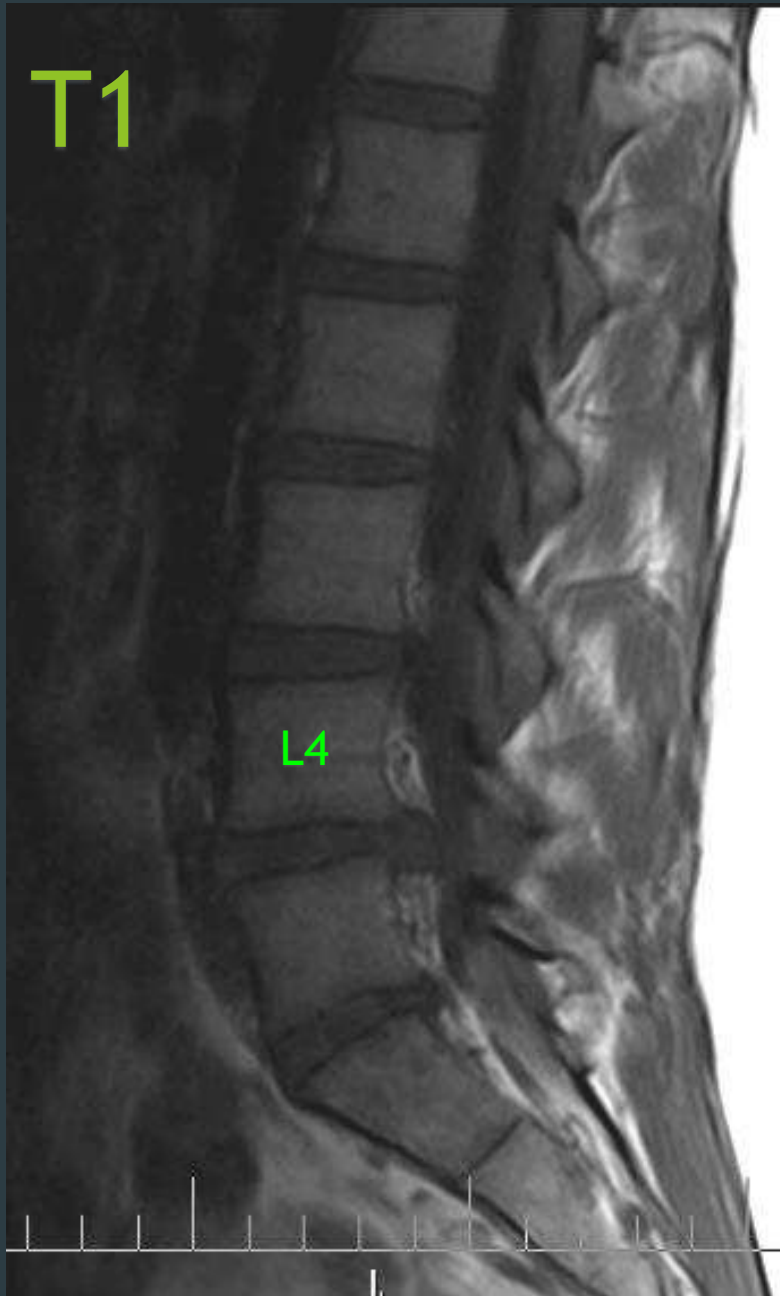Case 2

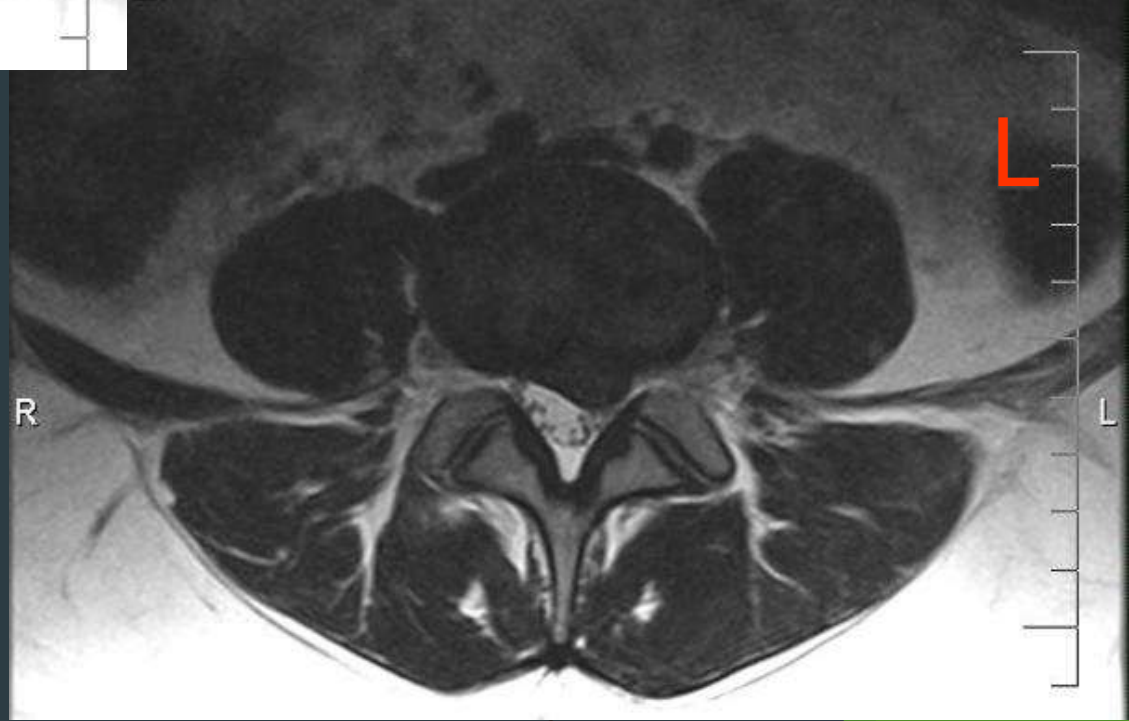
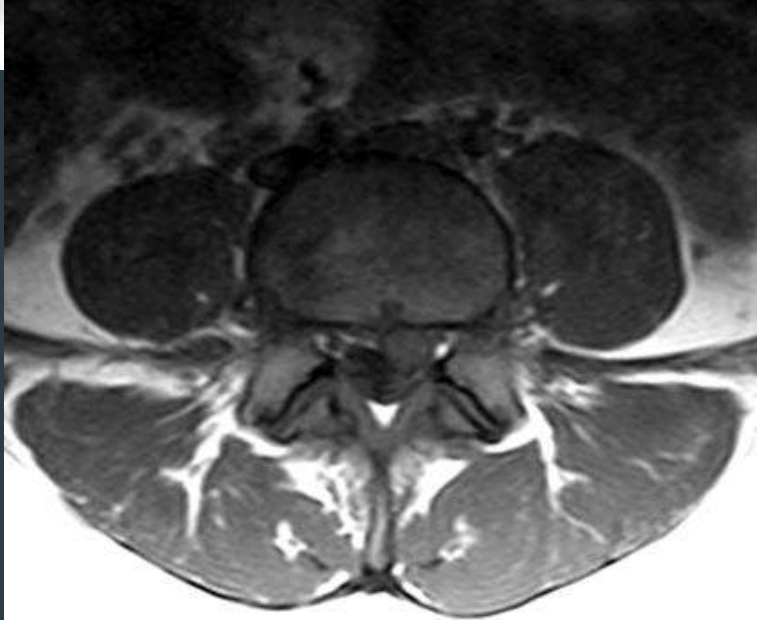
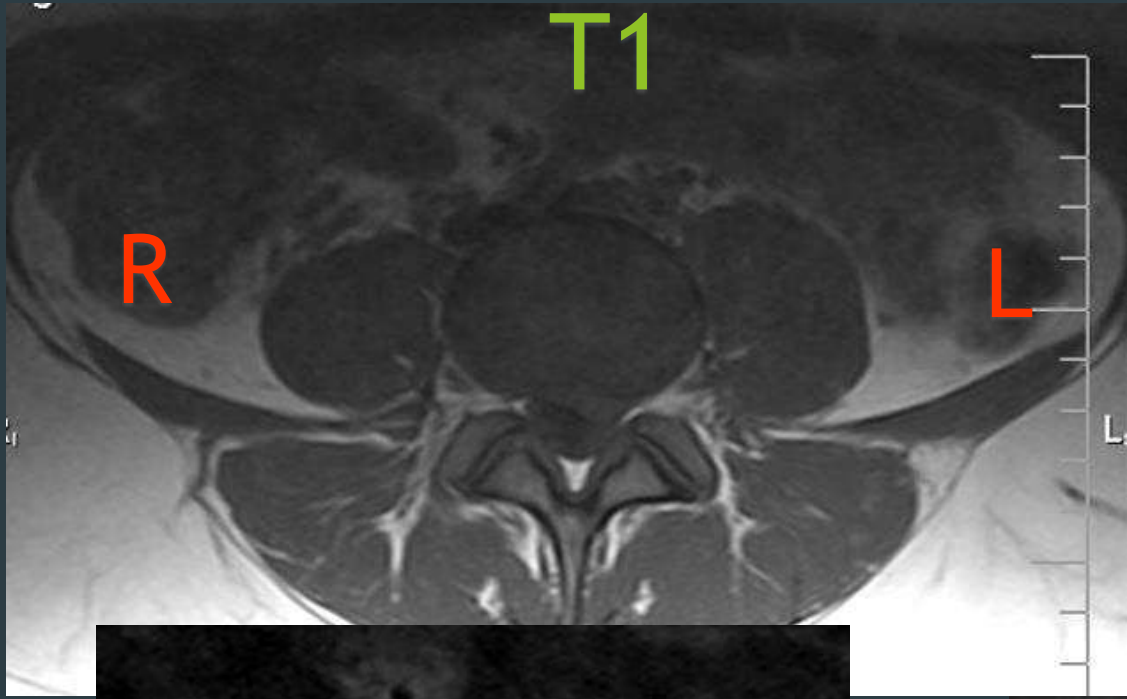
Sagittal T2 and Axial T2 weighted images



- No axial images available for disc level L5-S1

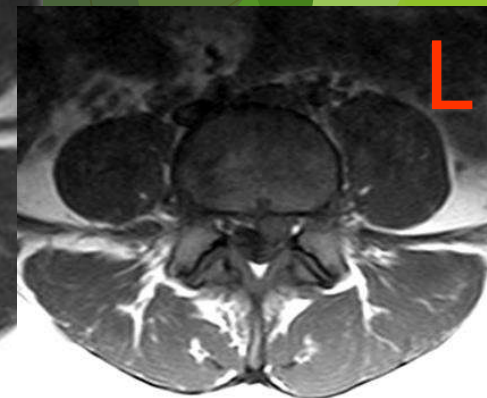
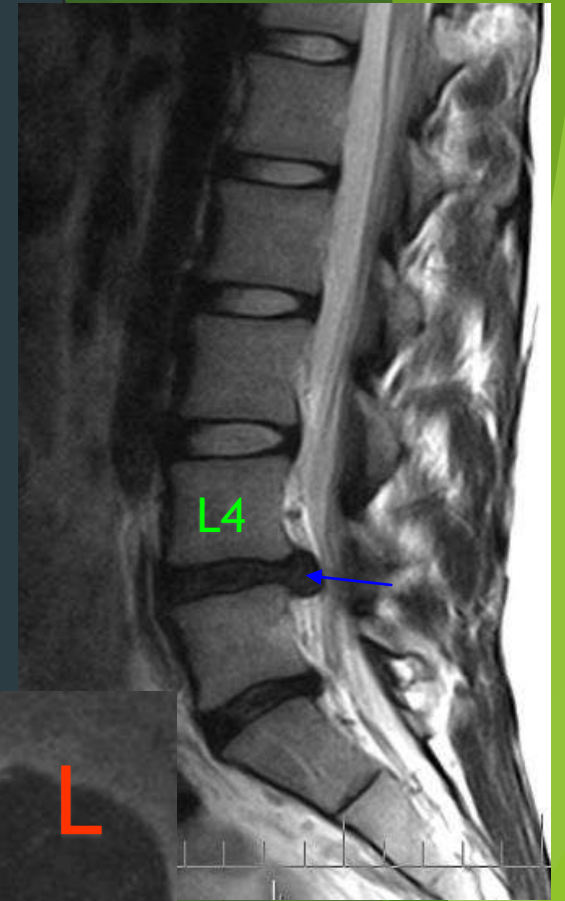
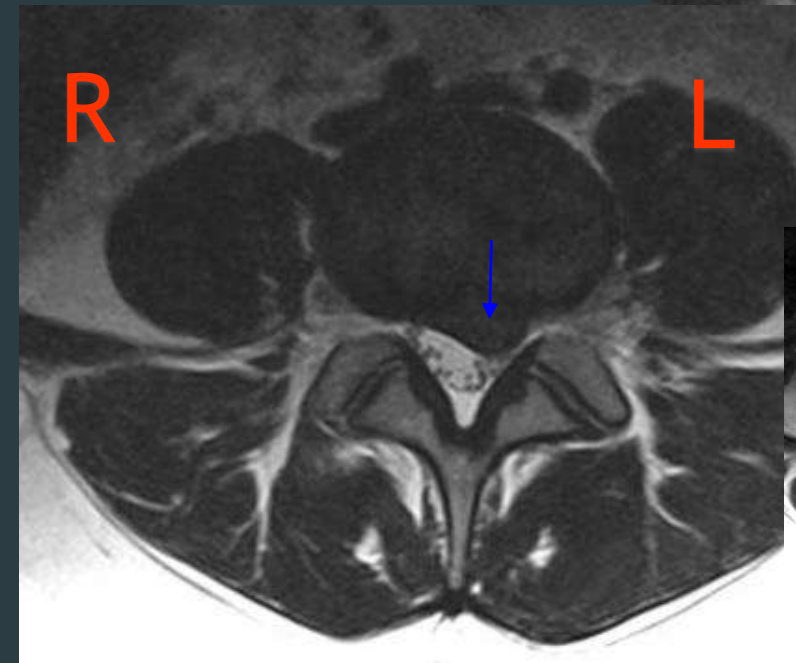






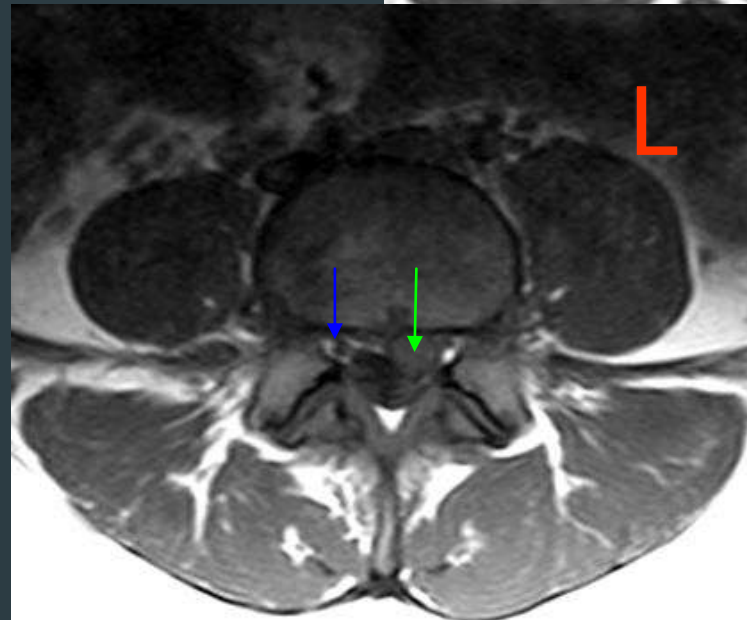
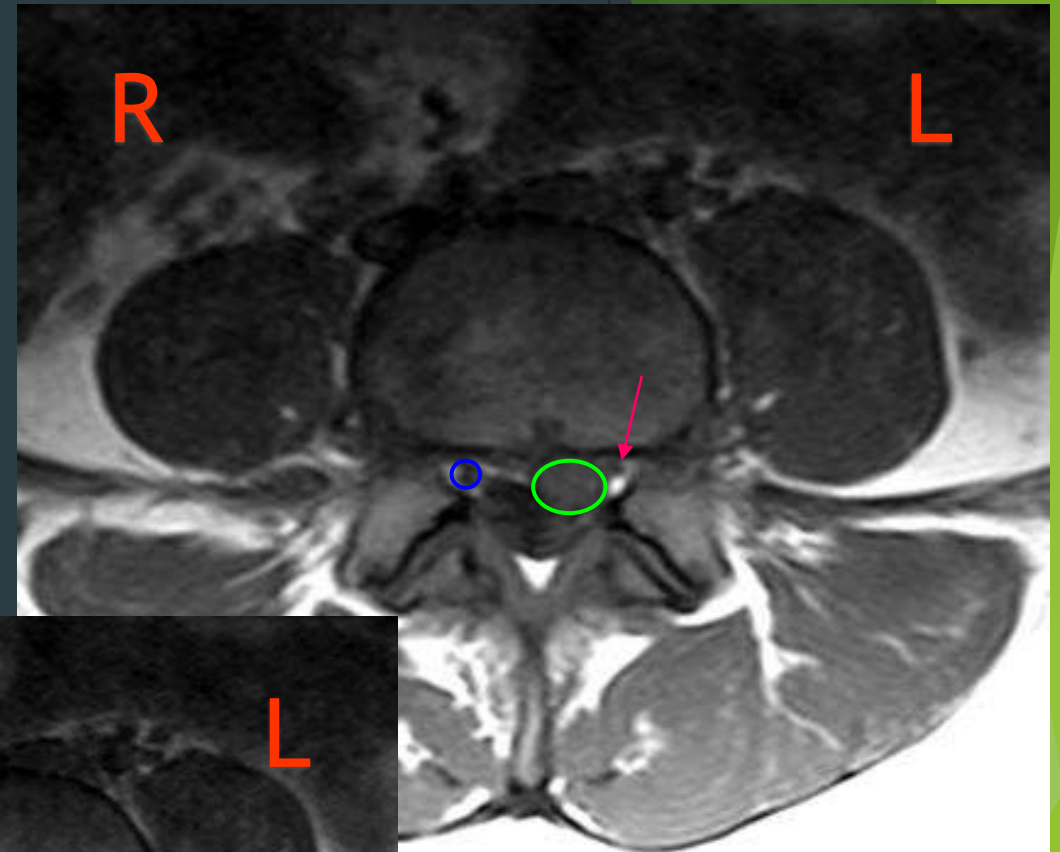
Diagnosis

- L4-L5: Left central disc extrusion (blue) with inferior migration is compressing the thecal sac and left L5 descending nerve root, resulting in moderate spinal canal stenosis.



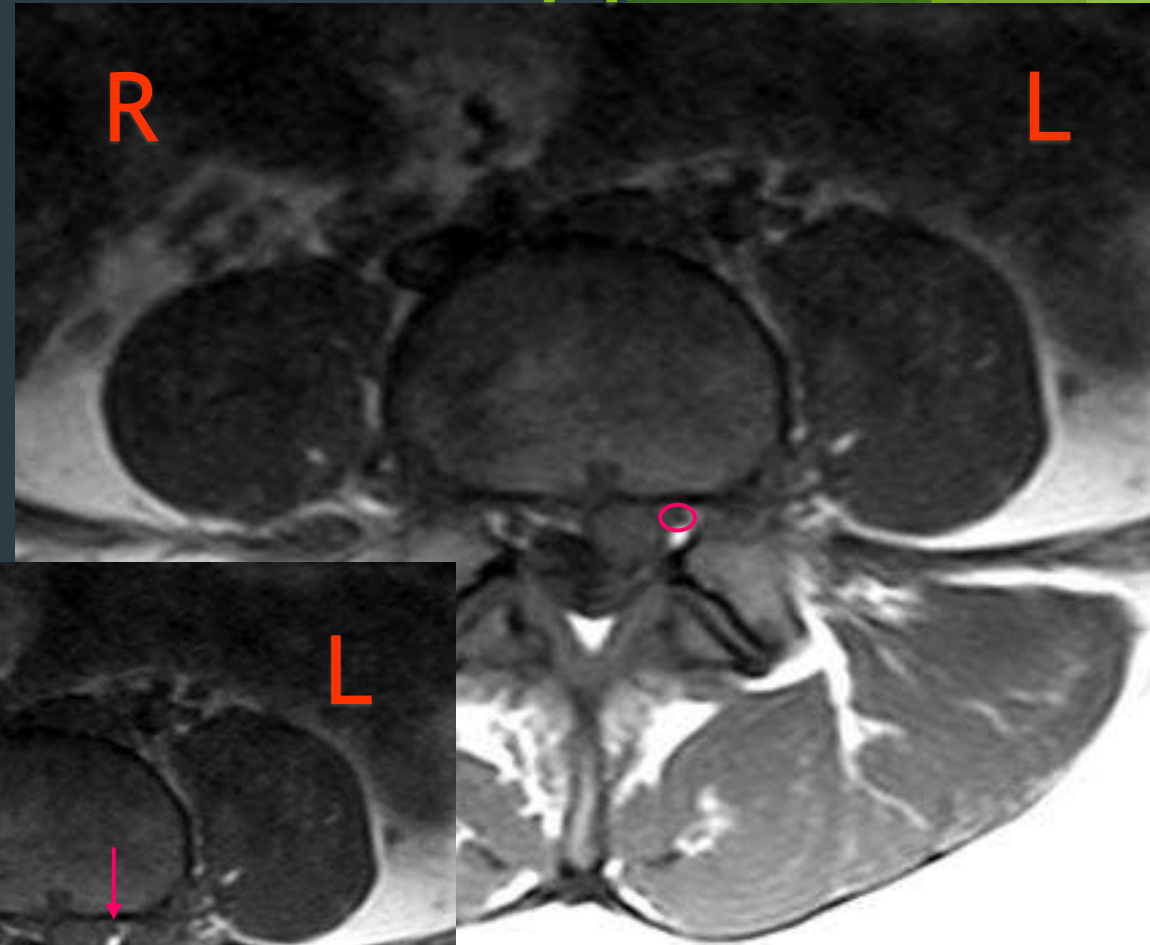
T1

- ▶ This is an axial T1 weighted image with the slice through the superior endplate of L5, traversing through the inferior migrated disc extrusion of L4-L5.
- ▶ Inferior migration of the disc extrusion (**green circle and arrow**) continues to compress the thecal sac and left L5 descending nerve root (**barely visible**).
- ▶ Right L5 descending nerve root (**blue circle and arrow**) is normal.



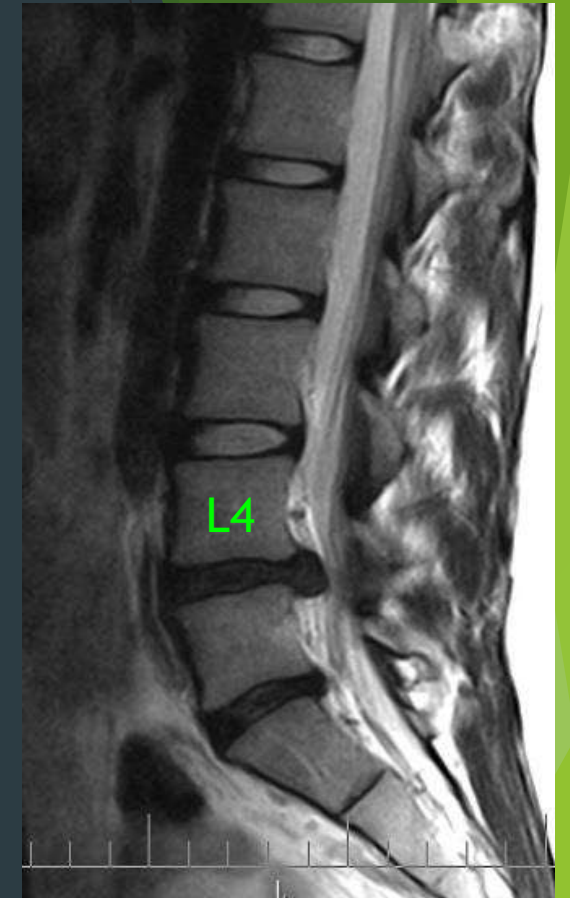T1

- ▶ This is an axial T1 weighted image slicing through the superior endplate of L5 and through the inferior migrated extrusion.
- ▶ Inferior migration of the disc extrusion continues to compress the thecal sac and left L5 descending nerve root (pink circle and arrow).
- ▶ Right L5 descending nerve root is normal.



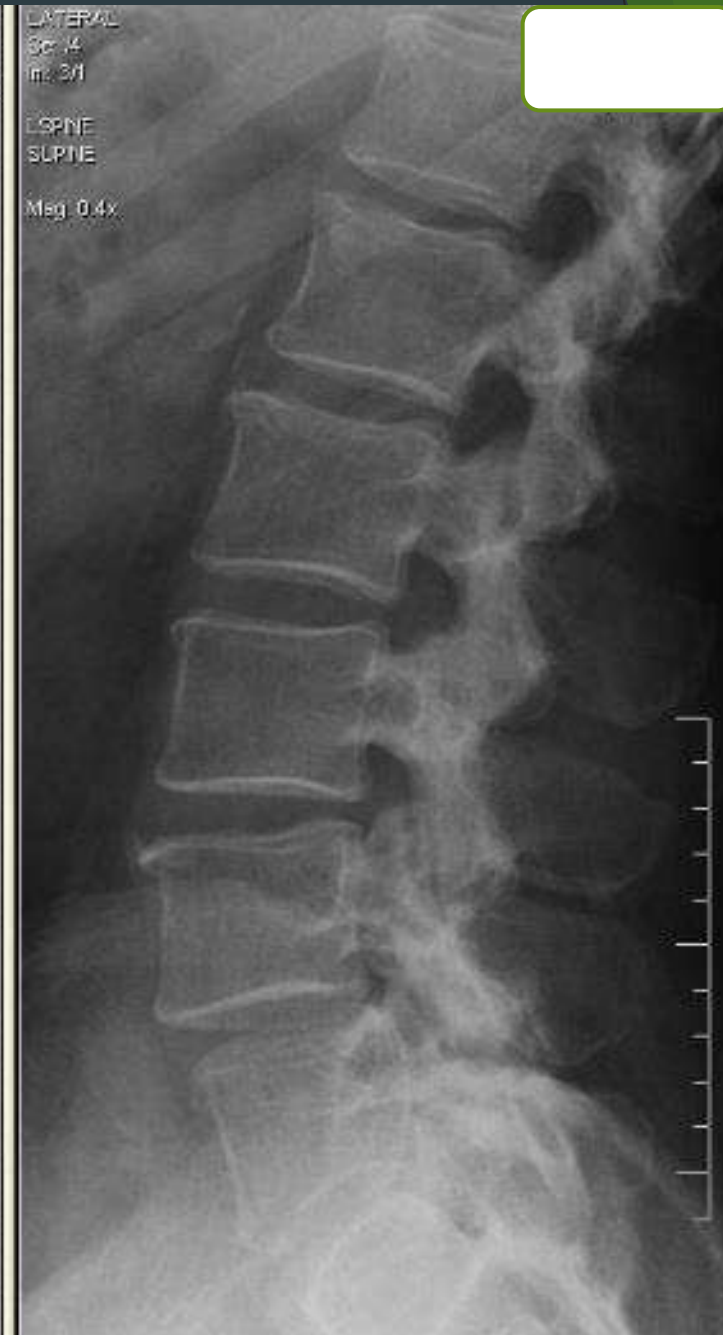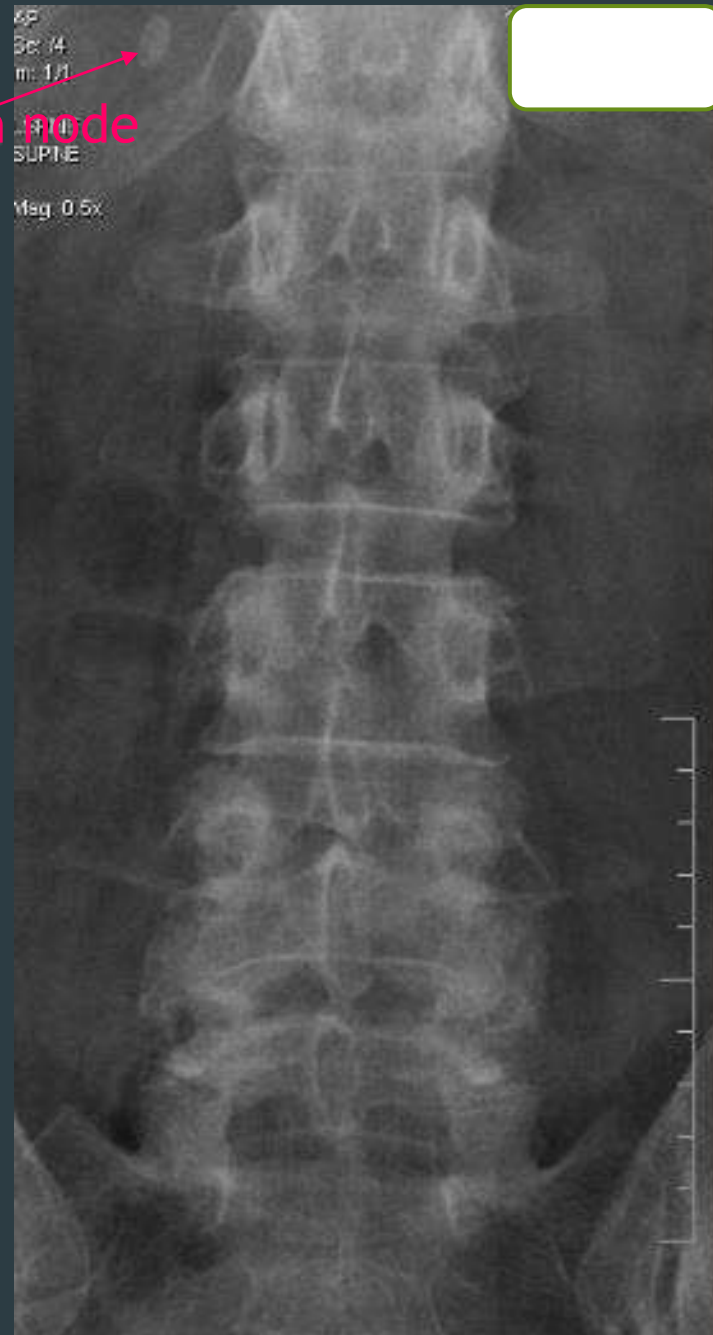Diagnosis

- ▶ L5-S1: Disc protrusion or diffuse disc bulge (axial images are not available).
- ▶ Mild disc narrowing with dehydration at L4-L5 and L5-S1.
- ▶ **Congenital small disc, known as hypoplastic disc**, at L5-S1.
- ▶ Normal: facet joints, muscles, bone, and ligamentum flavum are all normal.



Case 3: 65 year-old male

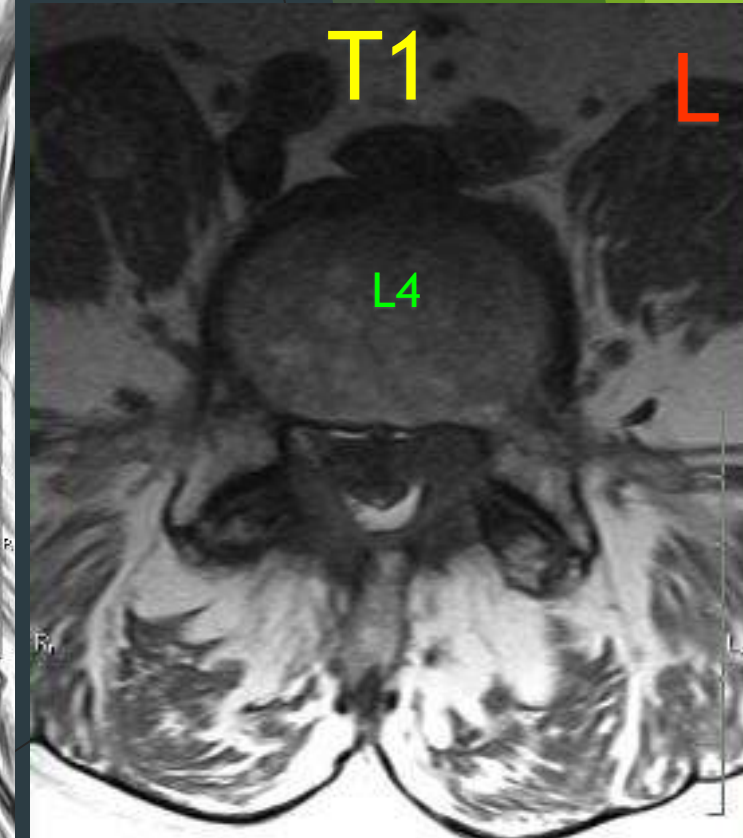
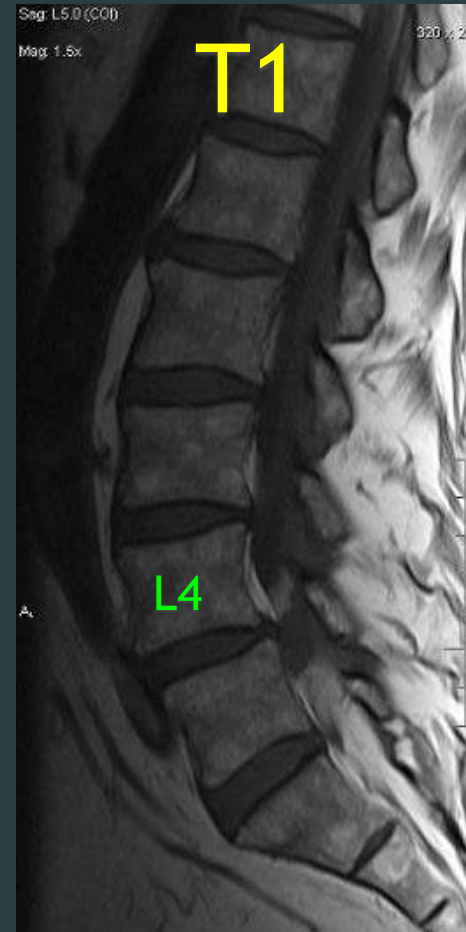
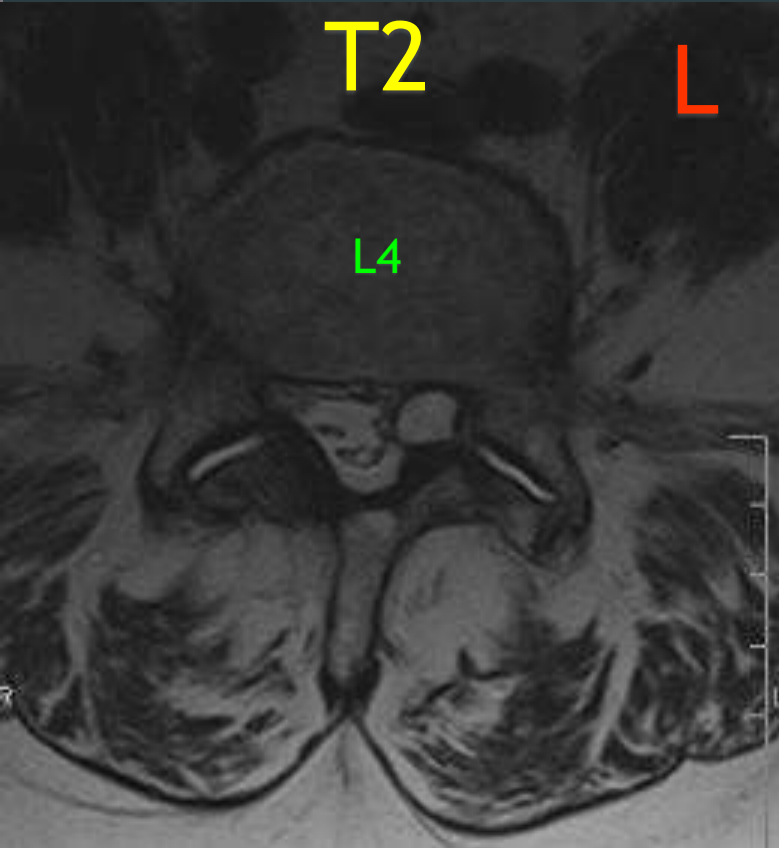
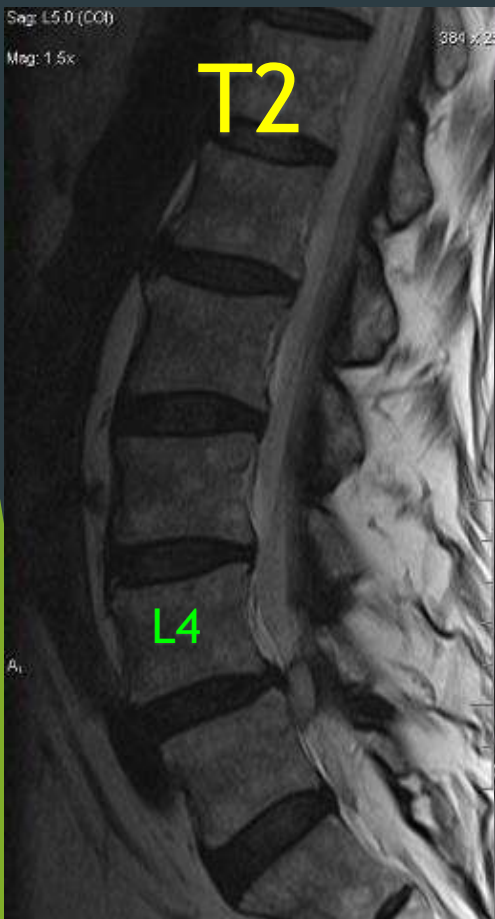Calcified lymph node



Diagnosis

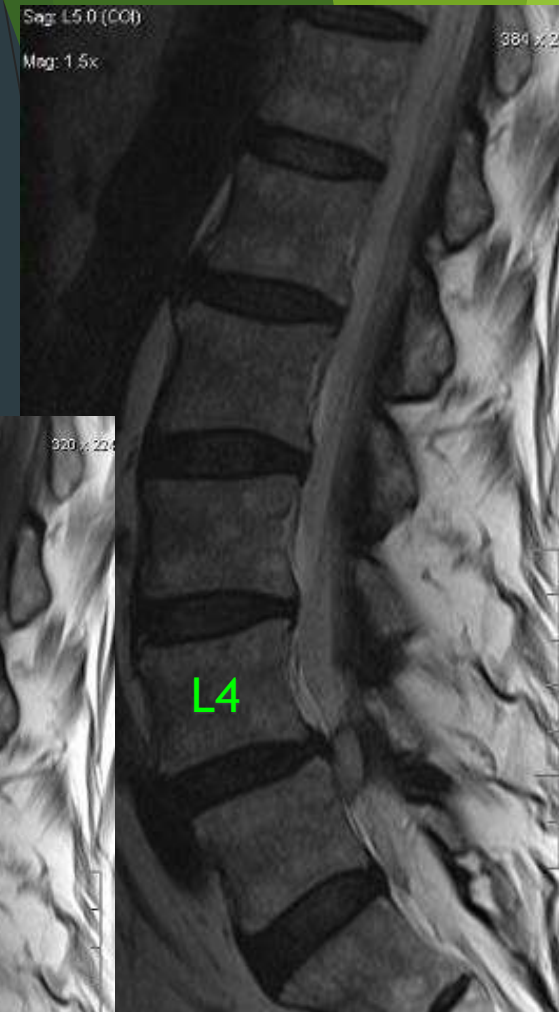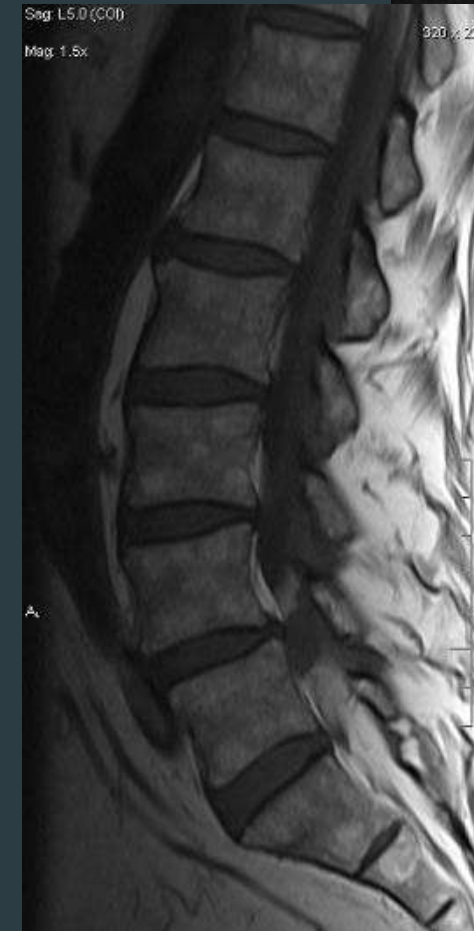- ▶ Degenerative disc disease at L3-L4, L4-L5 and L5-S1.
- ▶ Grade 1 degenerative anterolisthesis of L4 (intact pars interarticularis).
- ▶ Moderate facet arthrosis at L4-L5 and L5-S1, mild severity from L1-L2 to L3-L4.
- ▶ Generalized osteopenia, advanced for the patient's age.
- ▶ **Small calcified lymph node from previous infection within the upper right quadrant.**
- ▶ Advanced imaging and Why?
 - ▶ Reason for MRI: Osteopenia, degenerative changes, patient symptoms and not responding to care.
 - ▶ Note: **Differential diagnosis for osteopenia is metastatic disease, multiple myeloma, and lymphoma; medications, nutrition, inactivity, etc.**

Sagittal T2 and Axial T2; Sagittal T1 and Axial T1



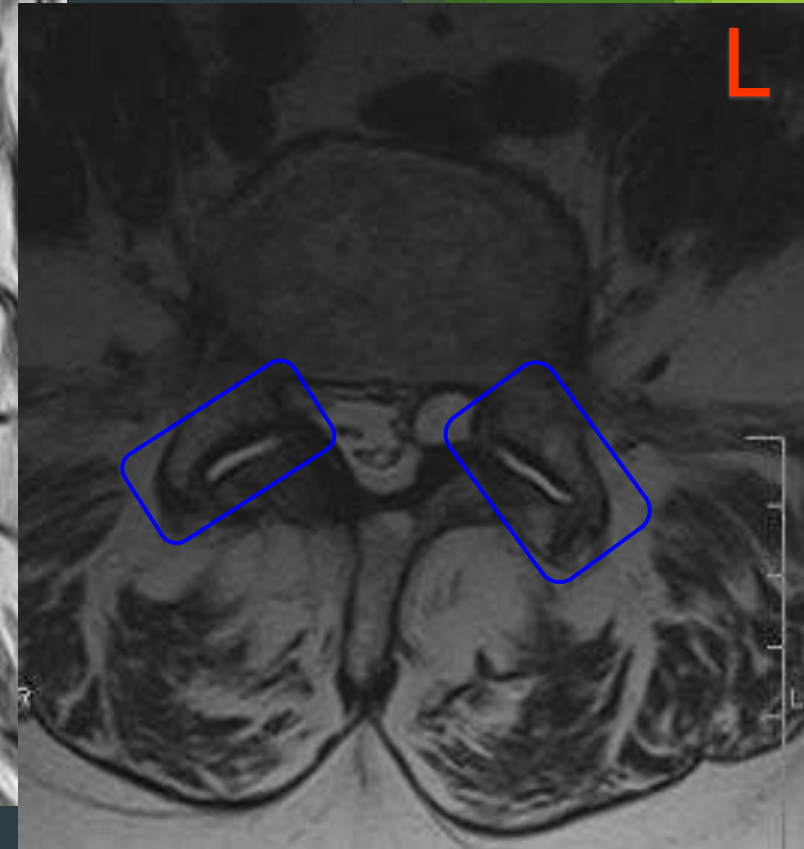
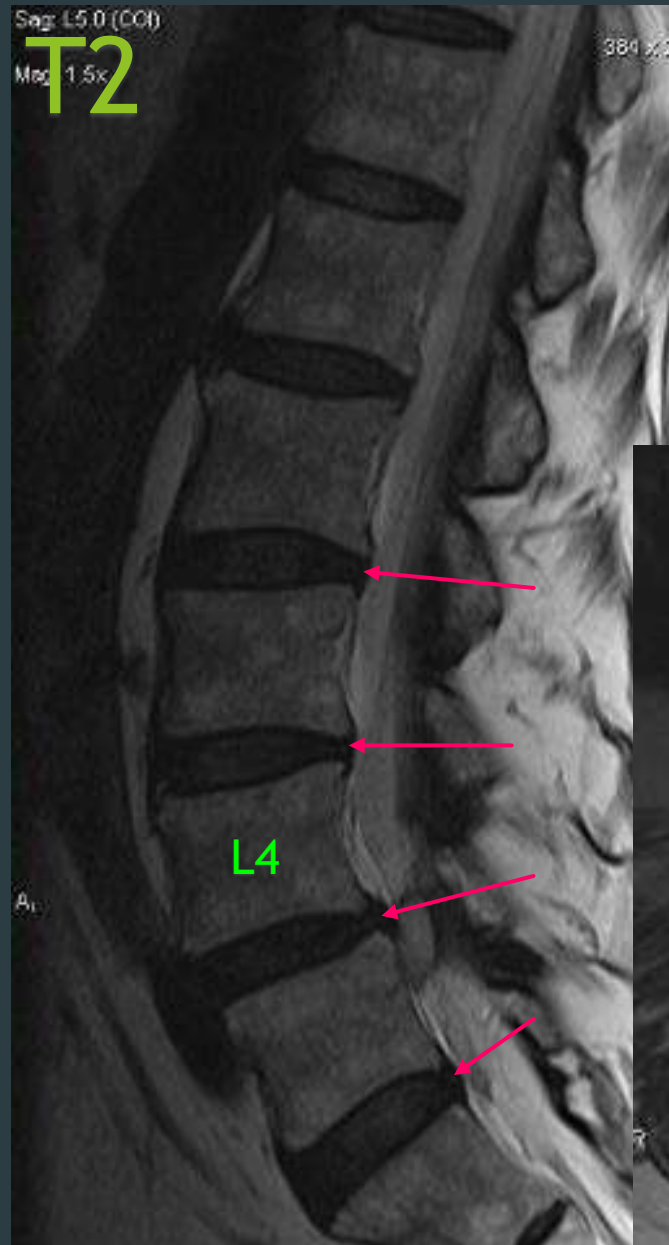
Diagnosis

- ▶ Fatty infiltration of the vertebral bodies, multilevel.
 - ▶ Multiple round-like or patchy signal intensities, bright on T1 and T2 weighted images.
 - ▶ This may be due osteopenia, medications, inactivity, obesity, etc.
 - ▶ This is not metastatic disease.



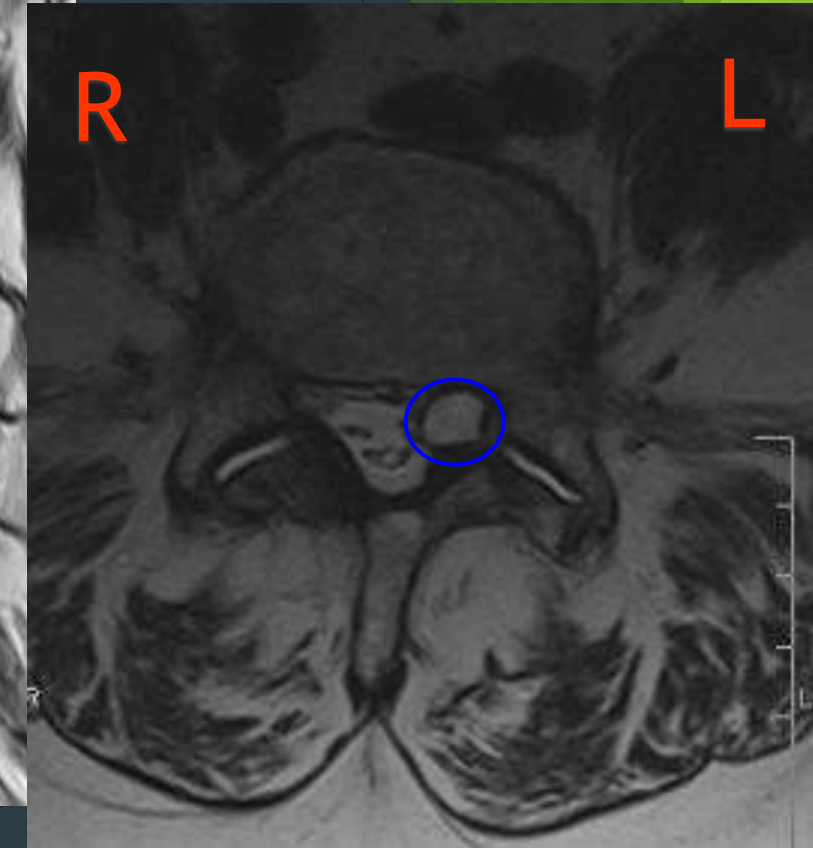
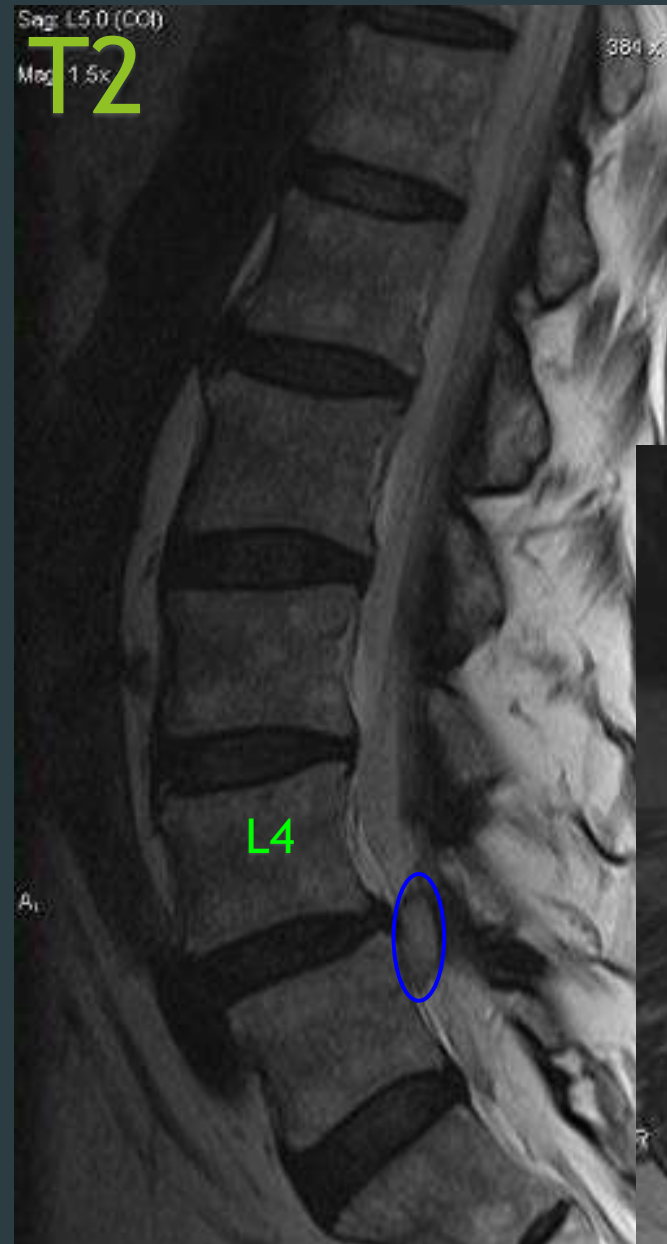Diagnosis

- ▶ Multilevel disc bulges with mild disc narrowing and dehydration, from L2-L3 to L5-S1 (**pink arrows**).
 - ▶ Parasagittal images is needed to evaluate the exiting nerve roots.
- ▶ Grade 1, Degenerative anterolisthesis at L4 (intact pars interarticularis).
- ▶ Moderate to severe bilateral facet arthrosis (**blue rectangle**) at L4-L5 (only axial image at L4-L5).



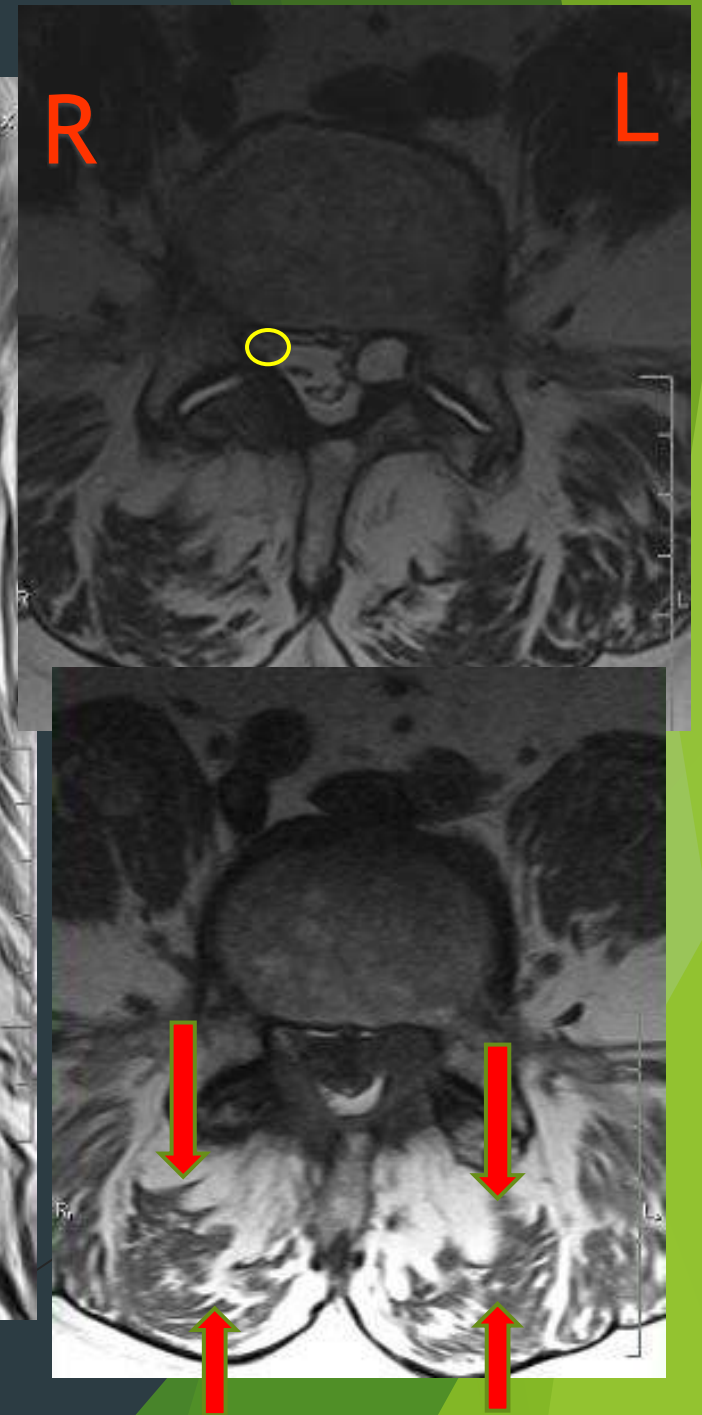
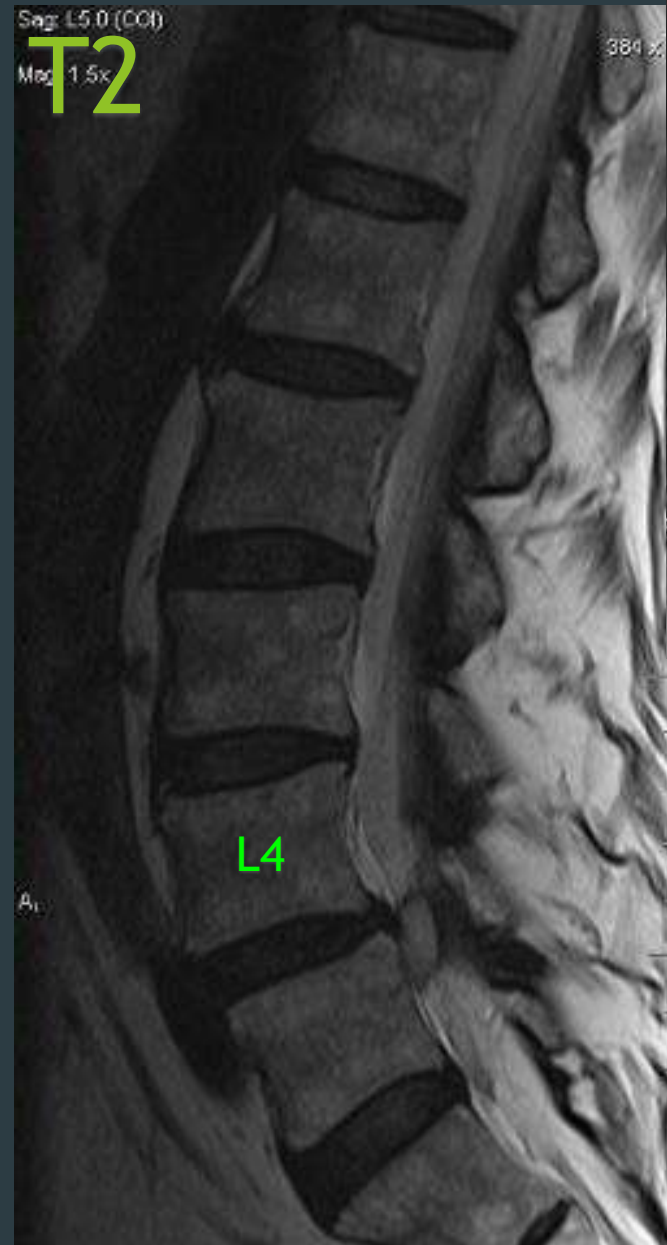Diagnosis

- ▶ Oval cyst-like lesion (blue oval) is noted within the left aspect of the spinal canal>>>This is a left facet cyst or synovial cyst
- ▶ Left facet cyst (blue oval) is compressing the thecal sac and left L5 descending nerve root, resulting in spinal canal stenosis.
 - ▶ The left descending nerve root is not visualized due to compression of the left facet cyst.



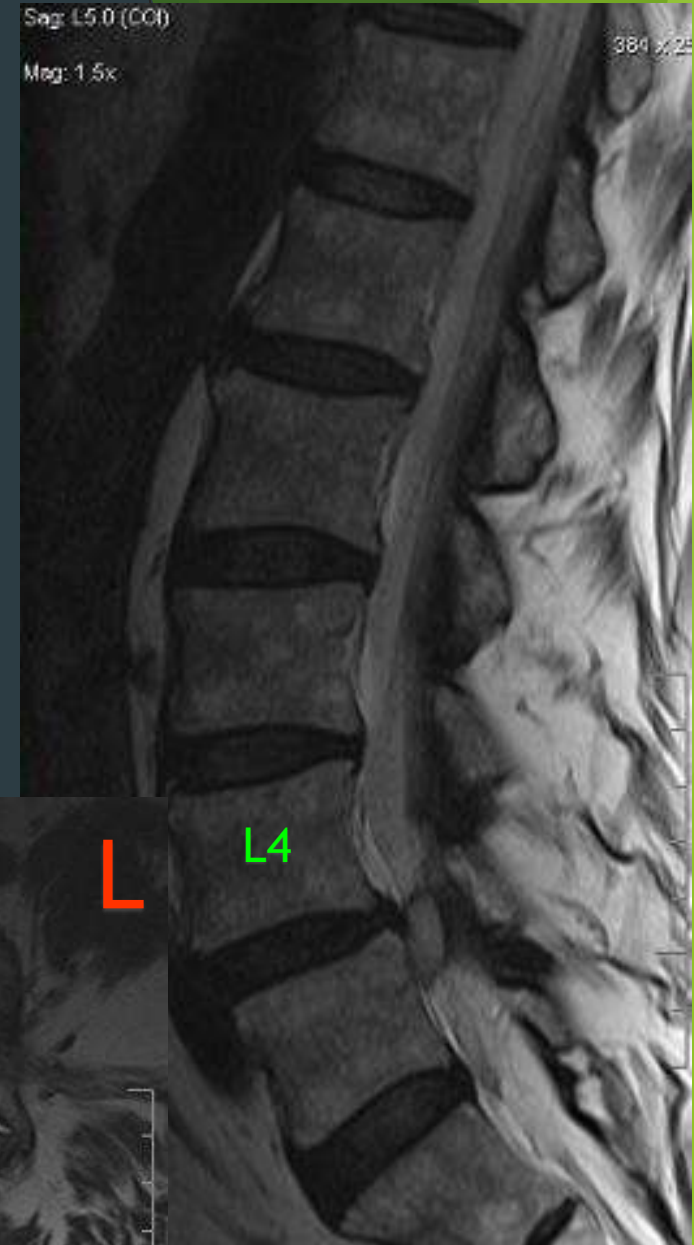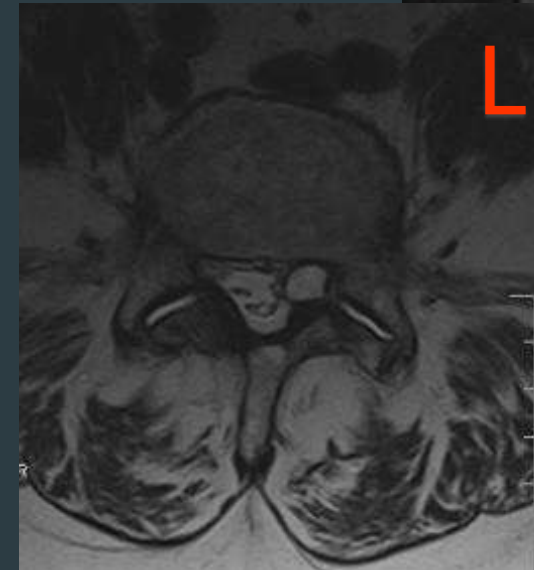
Diagnosis

- ▶ Fatty infiltration of the dorsal musculature (red arrow).
 - ▶ Cause of fatty infiltration: chronic pain, inactivity, or body habitus.
- ▶ Normal right L5 descending nerve root, shown on the axial image, (yellow circle).

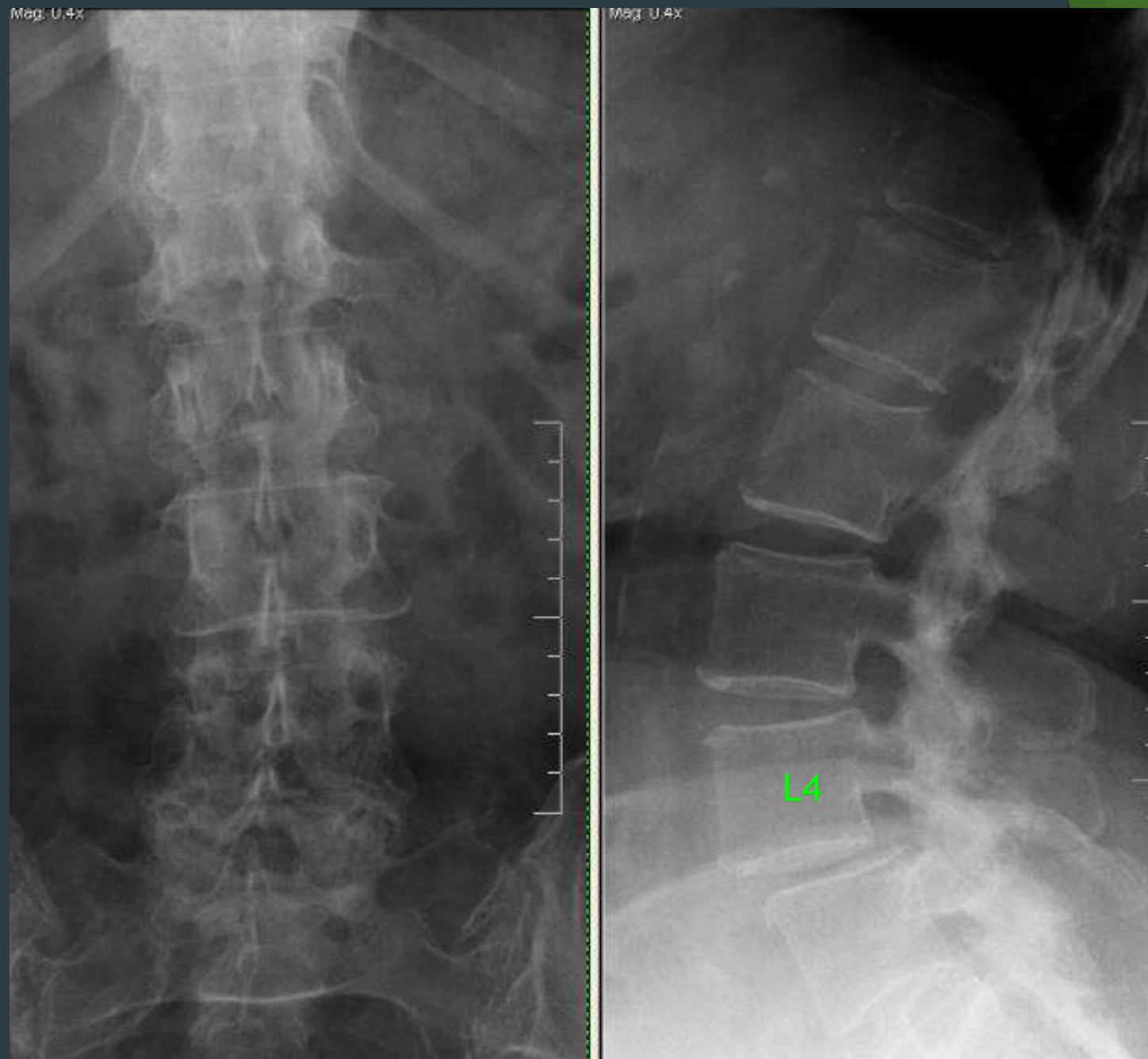


Synovial cyst/Facet cyst- Treatment

- ▶ **Chiropractic care**- can assist in shrinking the cyst.
- ▶ Corticosteroid injection- to shrink the cyst
- ▶ Surgical removal- depends on patient function; and failure to respond to trial conservative care and/or steroid injection.
- ▶ The cyst could potentially come back since the facet joints contain synovitis due to degenerative changes.



Case 4: 83 year old female

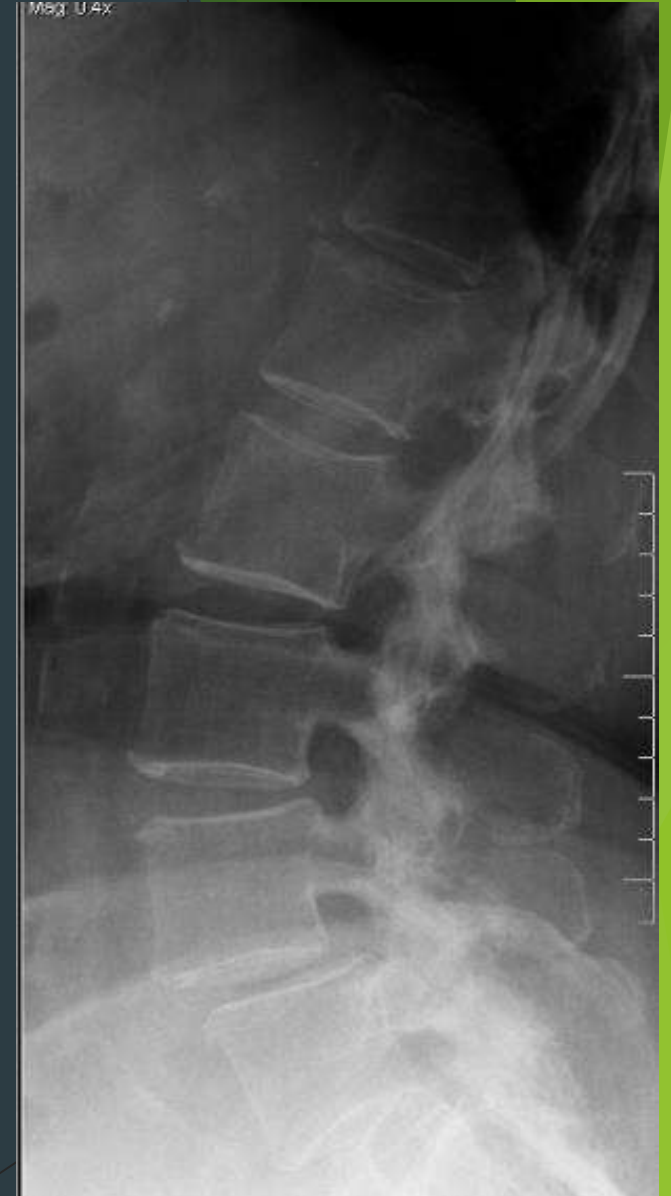

Diagnosis

- ▶ Degenerative disc disease from L3-L4 to L5-S1.
- ▶ Grade 1 degenerative anterolisthesis of L4 (intact pars interarticularis)>>>>cause of the anterolisthesis of L4 was degenerative changes.
- ▶ Moderate to severe facet arthrosis.
- ▶ Mild bilateral sacroiliac arthrosis.
- ▶ Shallow left convexity of the lumbar spine.
- ▶ Anterior shift in weightbearing of the lumbar spine.
- ▶ Generalized osteopenia. Clinically correlate.
- ▶ Atherosclerosis of the abdominal aorta, on the lateral radiograph.

Diagnosis

- ▶ Atherosclerosis of the abdominal aorta, on the lateral radiograph.
 - ▶ Normal diameter of the abdominal aorta is 2.0 cm; anything greater requires follow-up with Doppler ultrasound or CT with/without contrast.
 - ▶ This patients abdominal aorta is normal in diameter.



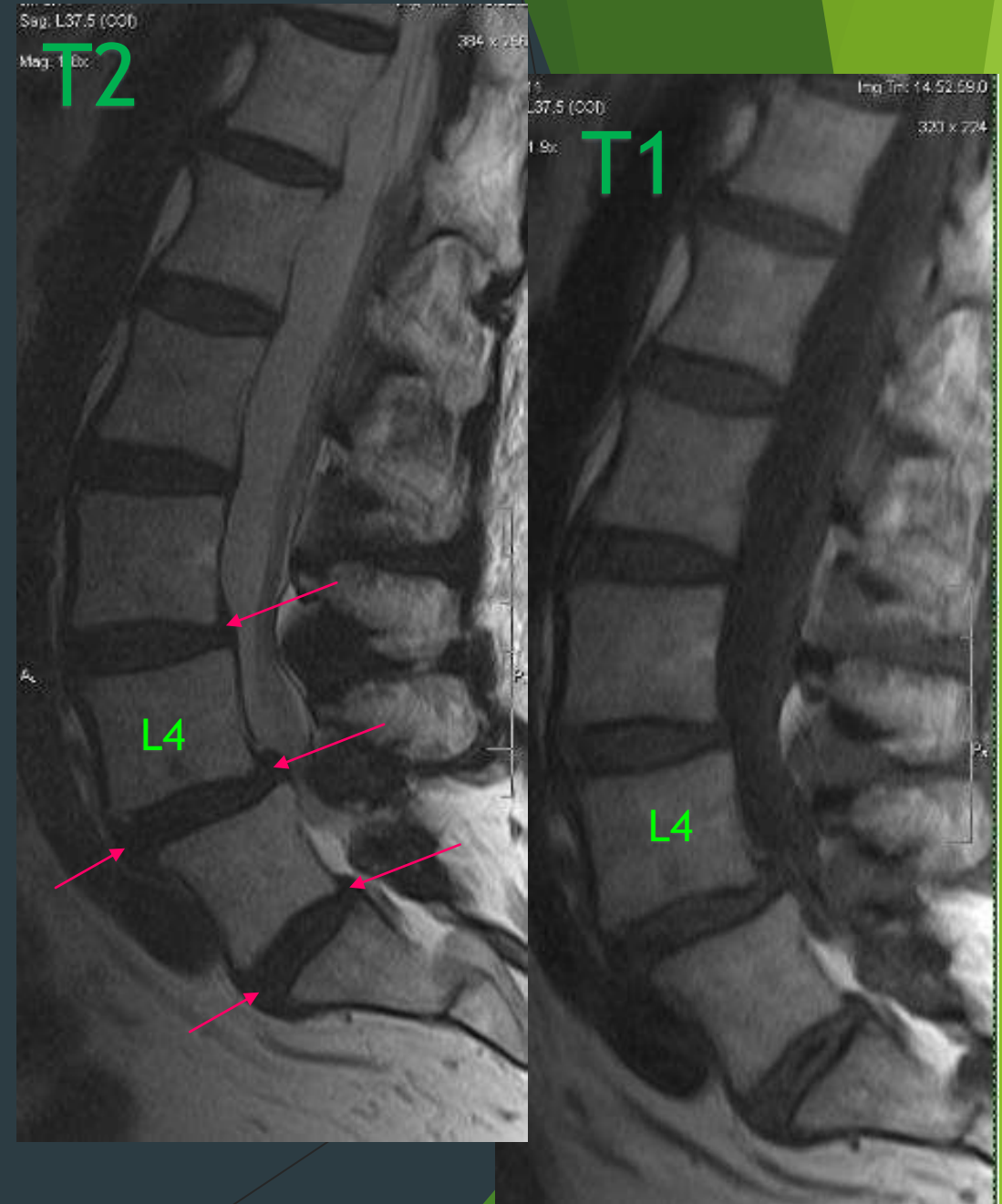
Diagnosis----What's the next step to manage this patient?

► Advanced imaging and Why?

- Reasons for MRI: Degenerative changes, patient symptoms and not responding to care; and generalized osteopenia.
- If osteopenia is a concern....differential diagnosis is metastatic disease, multiple myeloma, and lymphoma, etc. MRI can help in detecting pathologic bony lesions.

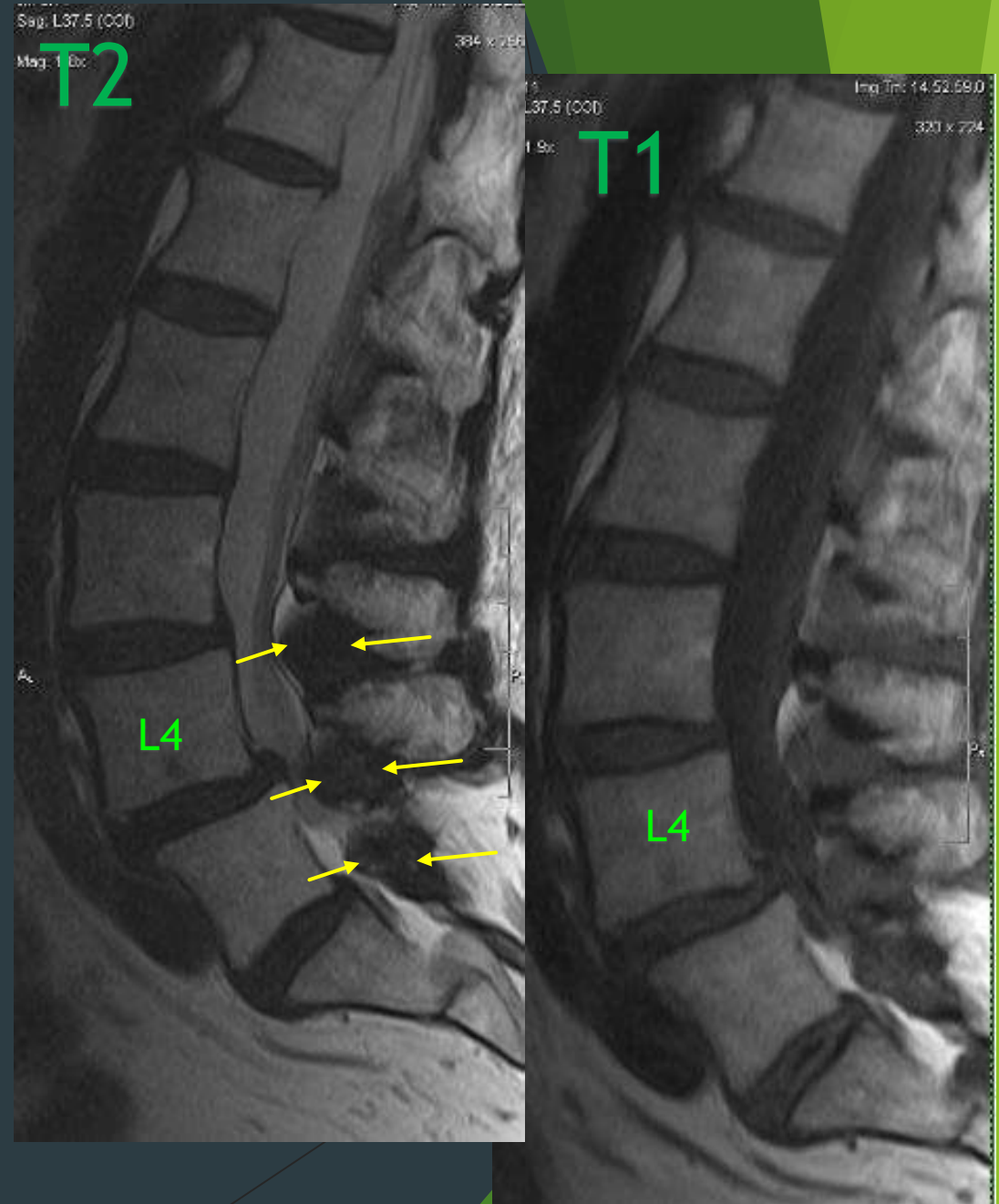
Sagittal T2 and T1

- ▶ Diffuse disc bulge (**pink arrows**) at T12-L1, L3-L4, L4-L5 and L5-S1 is compressing the thecal sac.
- ▶ Mild degenerative disc disease from L3-L4 to L5-S1, with disc narrowing and disc desiccation/dehydration.
- ▶ L4: Degenerative anterolisthesis, Grade 1 (The pars interarticularis are intact).



Sagittal T2 and T1

- ▶ Thickening of ligamentum flavum (**yellow arrows**), along the anterior aspect of the lamina from L3 to L5.
- ▶ Spinal canal stenosis is due to disc bulges AND ligamentum flavum thickening, resulting in:
 - ▶ Mild spinal canal stenosis at L3-L4.
 - ▶ Severe spinal canal stenosis at L4-L5 and L5-S1.



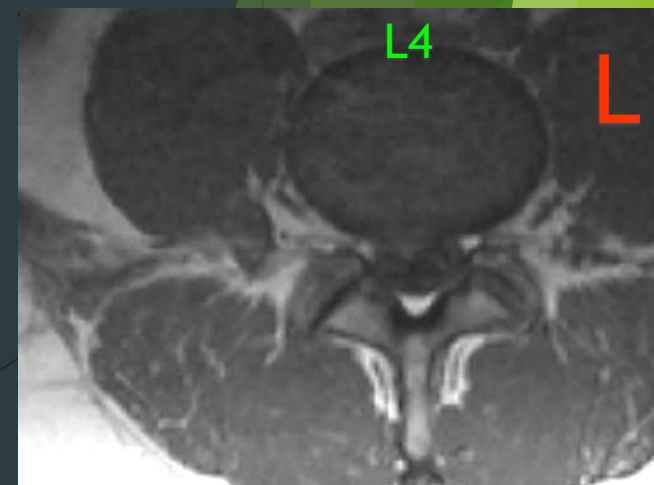
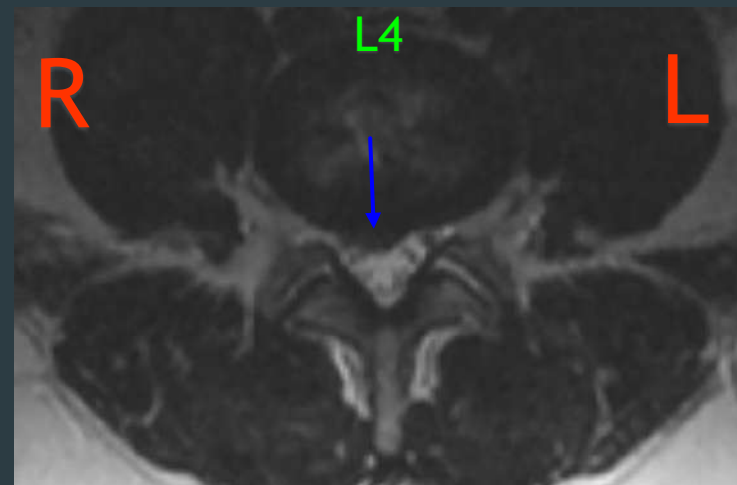
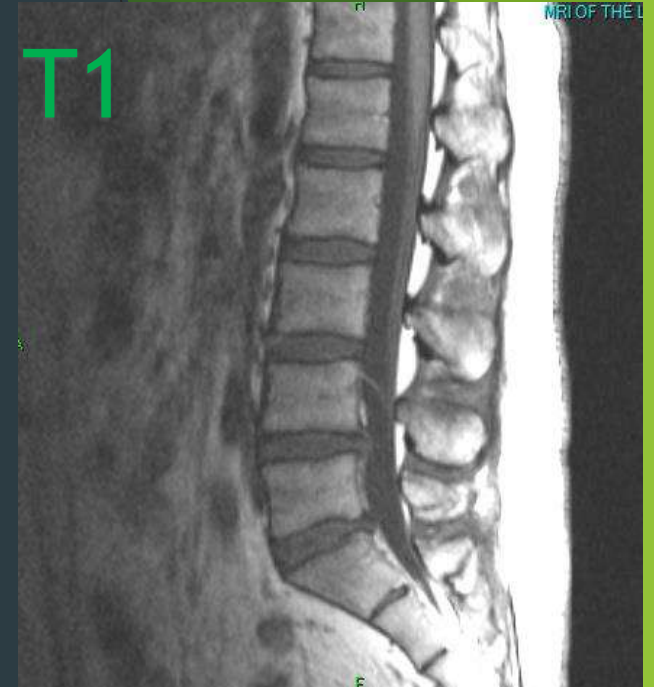
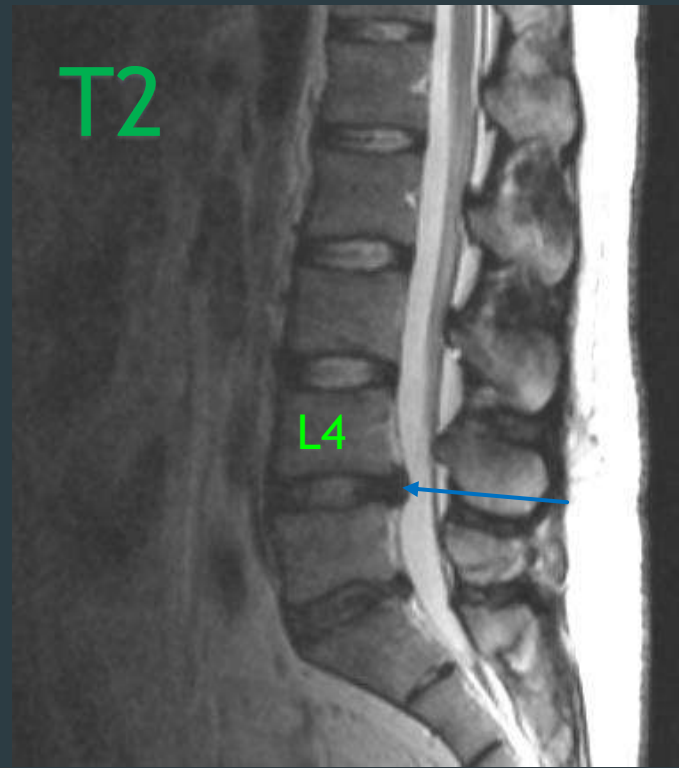
Spinal Canal Stenosis

► Treatment:

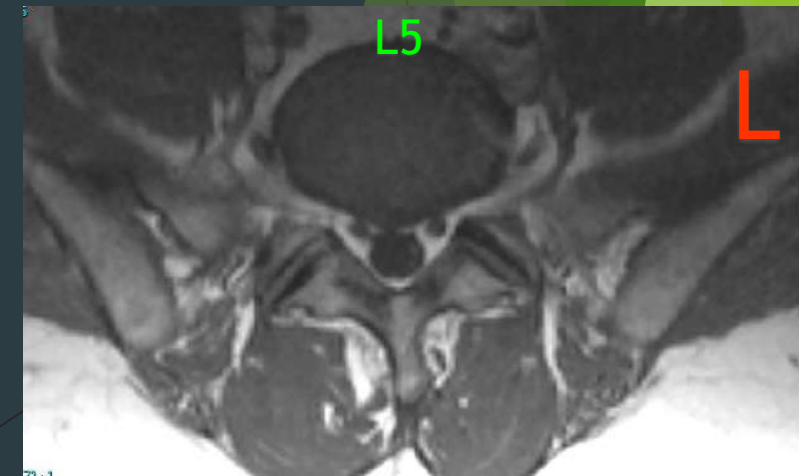
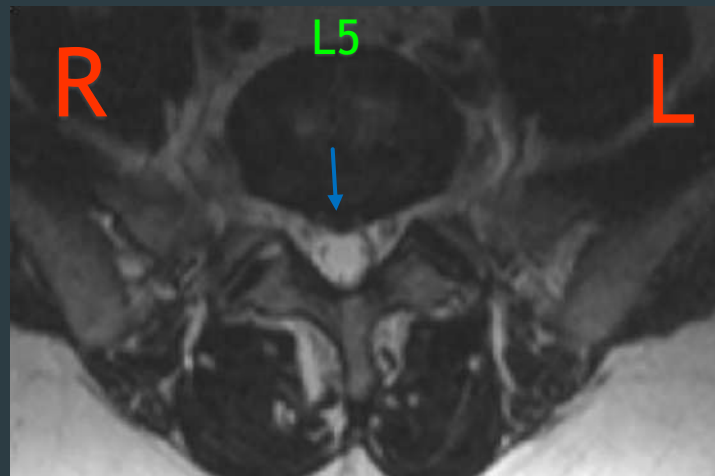
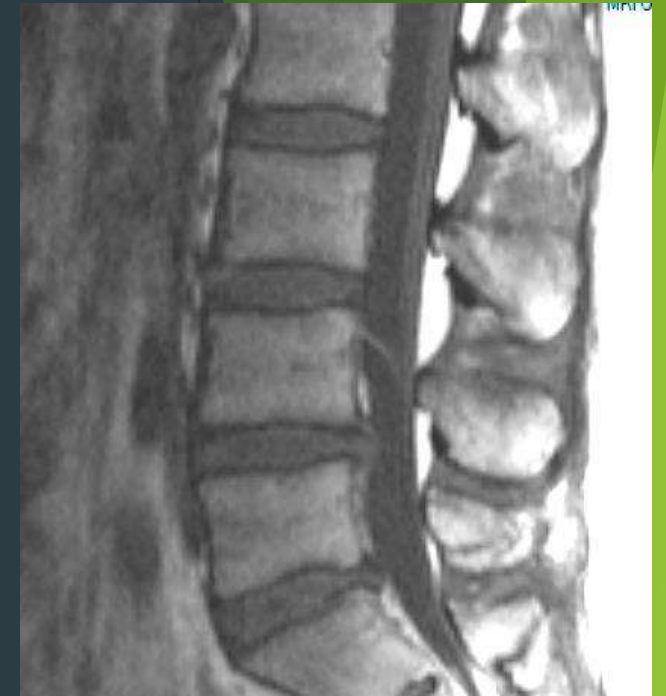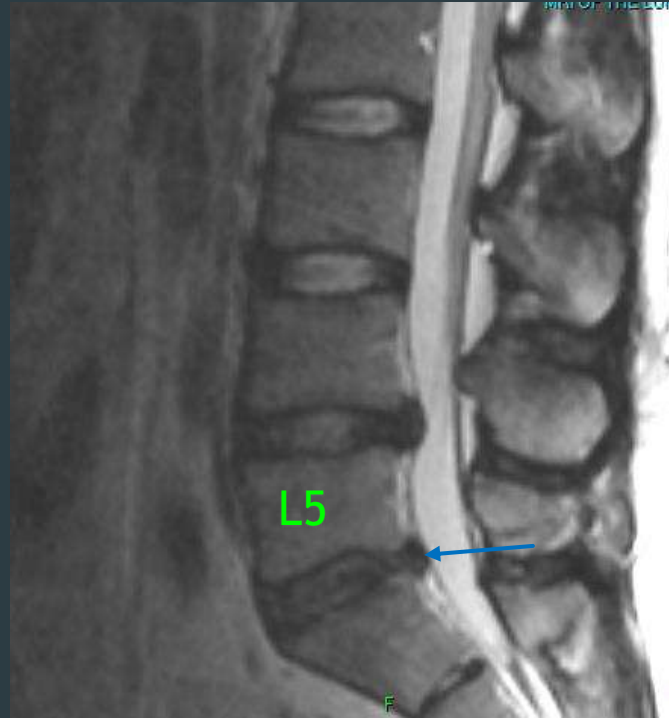
- Chiropractic- Stenosis is difficult to treat. One day, you treat the patient and they respond favorably. At the next visit, the patient receives the same treatment and they flare up. Stenosis has its good and bad days. In Chiropractic, we have many tools and a variety of ways to treat stenosis.
- Surgery- In this case, I do not know the symptoms or the function of the patient. If conservative treatment has been tried and patient function is poor, then surgical intervention could be considered. In order to open the spinal canal, multilevel laminectomy would be performed. Now I realize this is an elderly patient...so they may not want surgery or they may not be a surgical candidate.

Case 5: Low back pain and radiculopathy

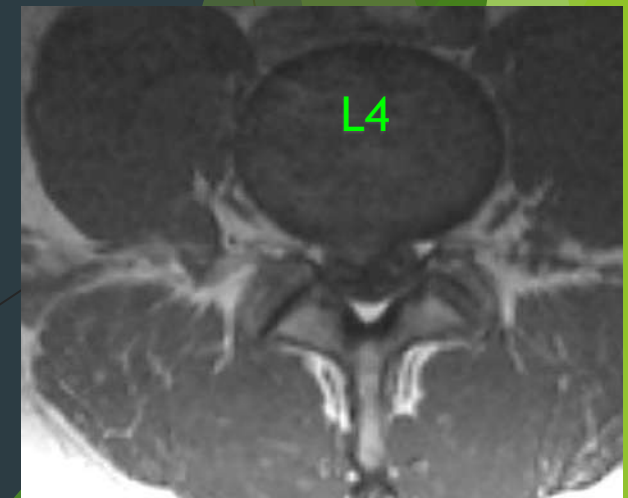
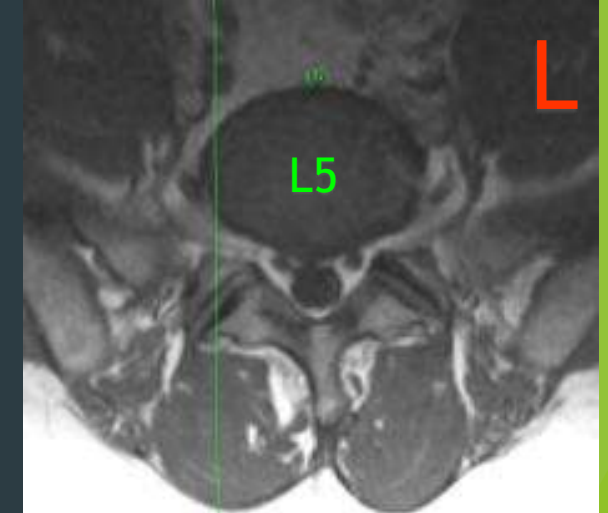
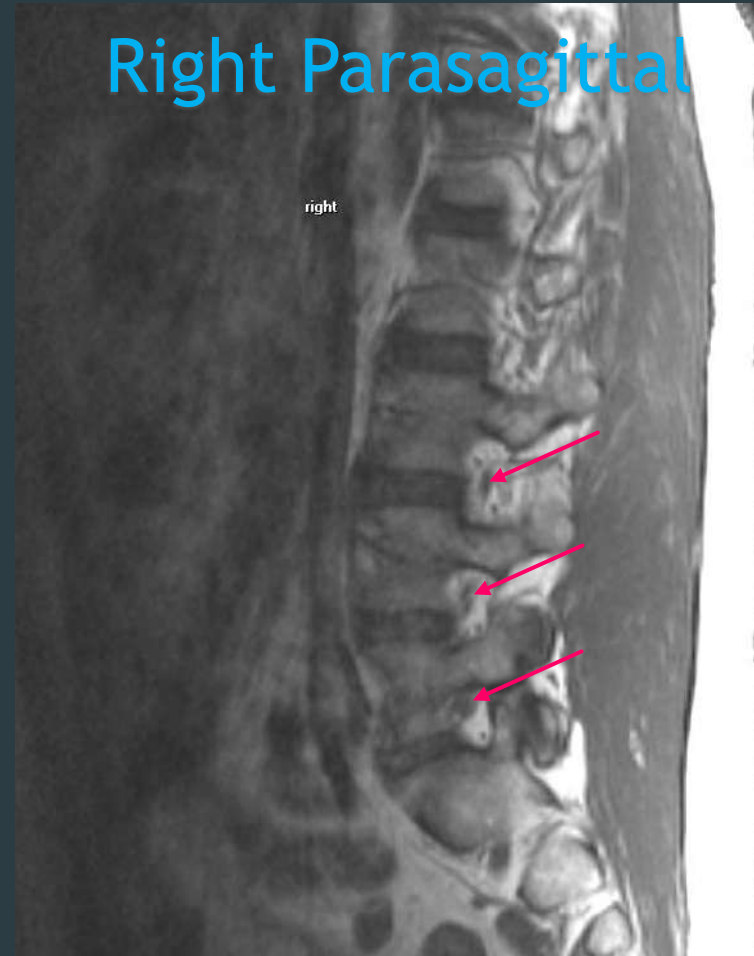
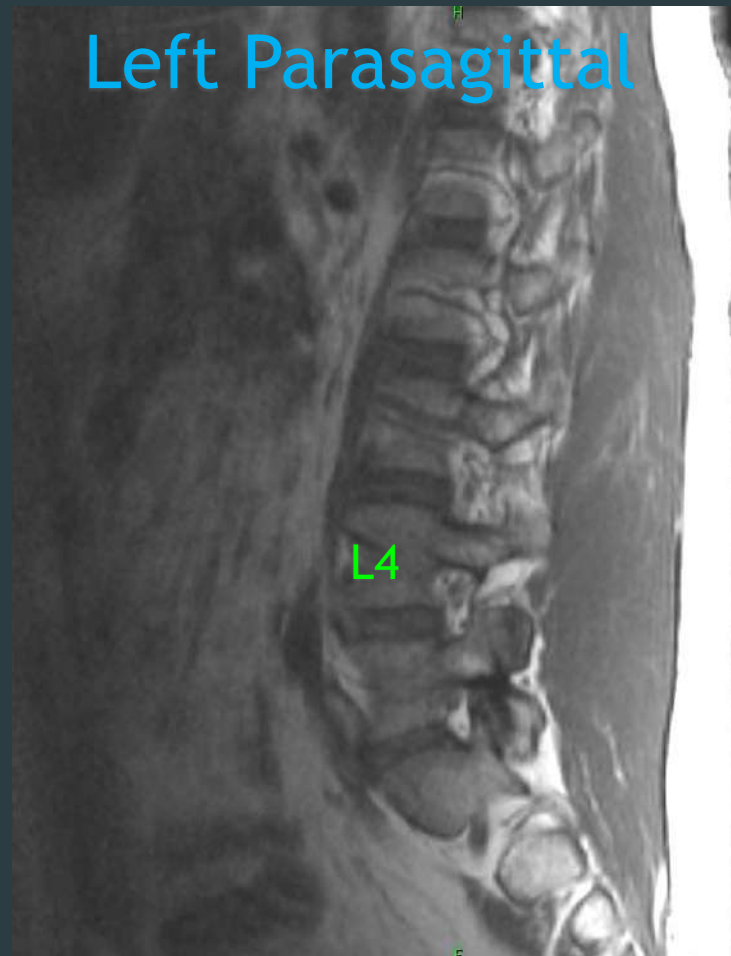L4-L5 Disc



L5-S1 Disc

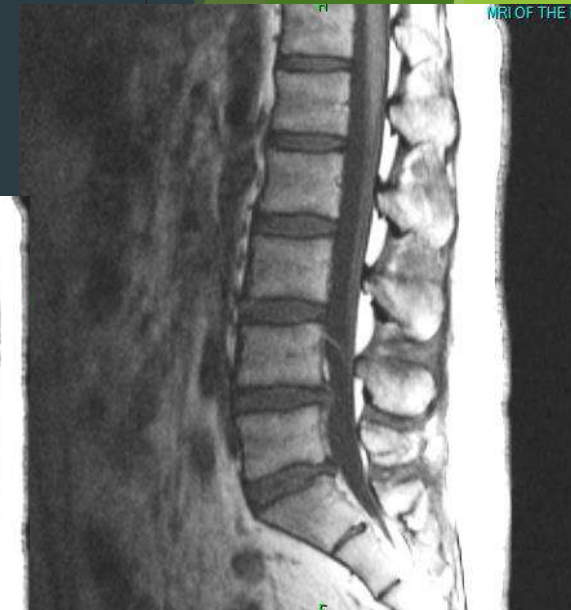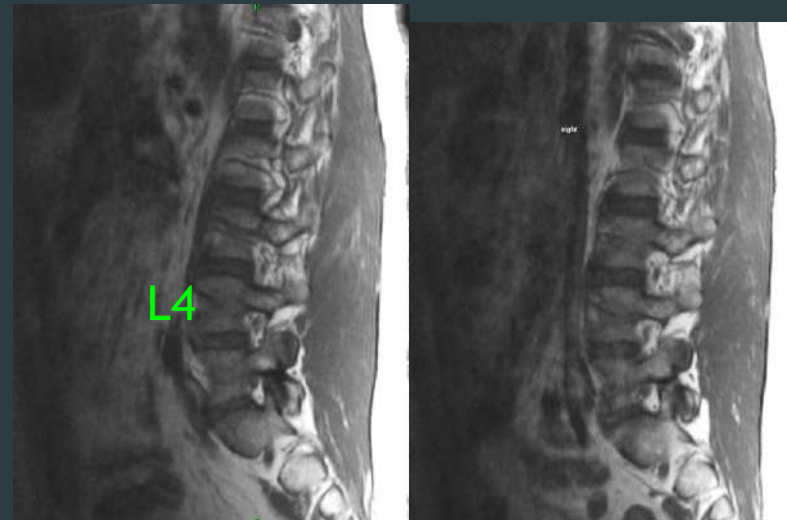
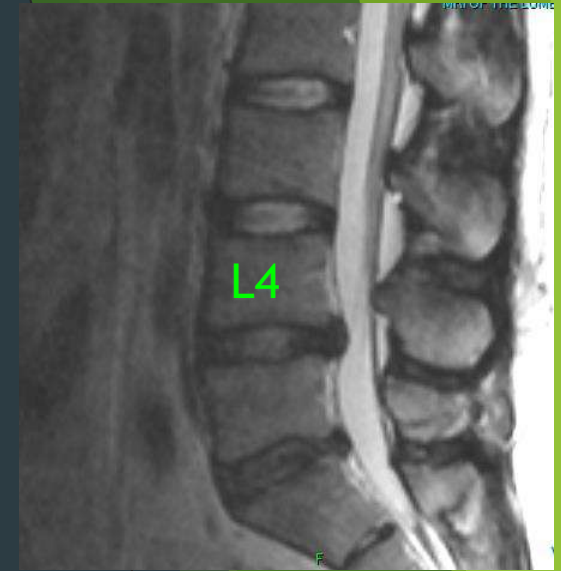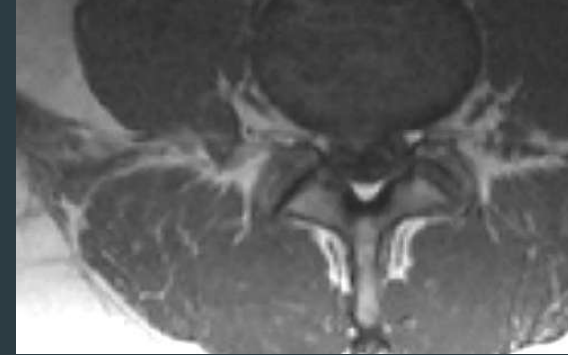
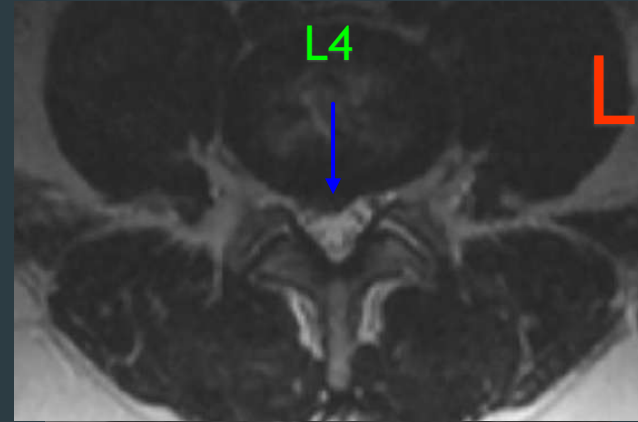


Left & Right Parasagittal Images: No neural foramina stenosis, and normal exiting nerve roots (pink arrows)



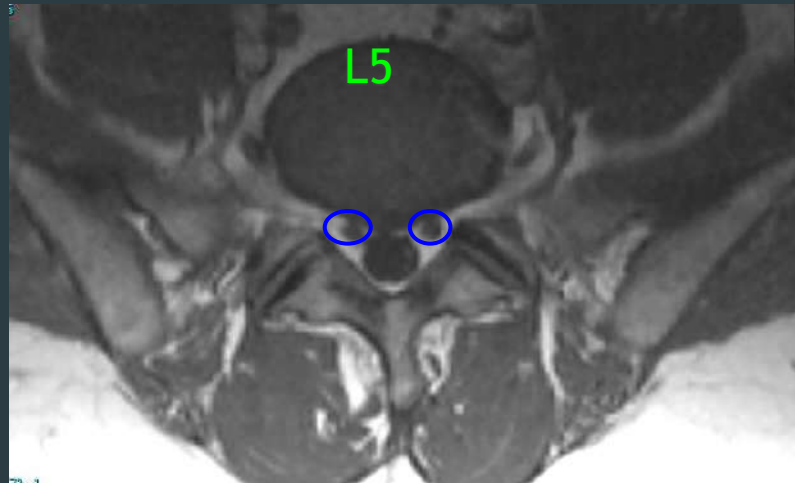
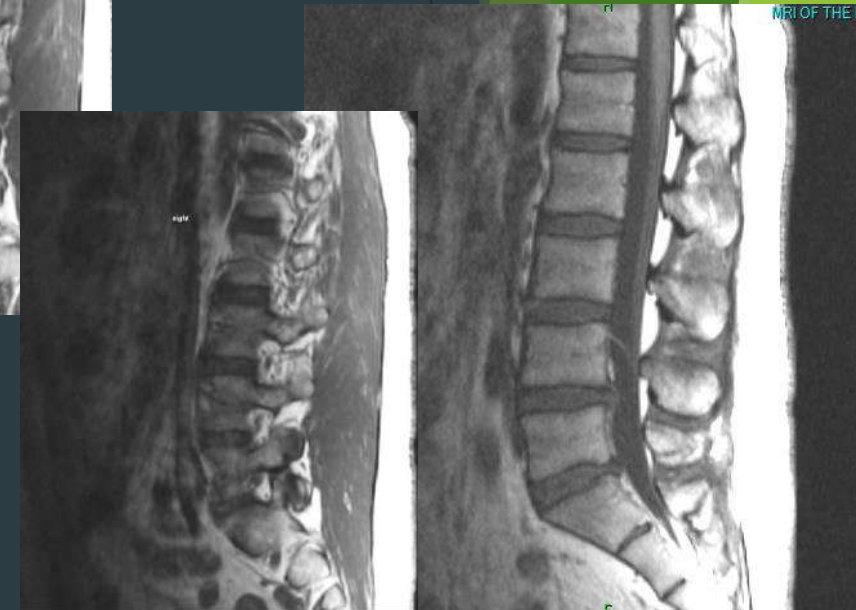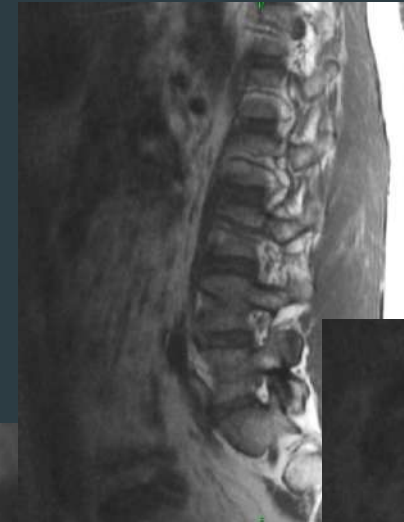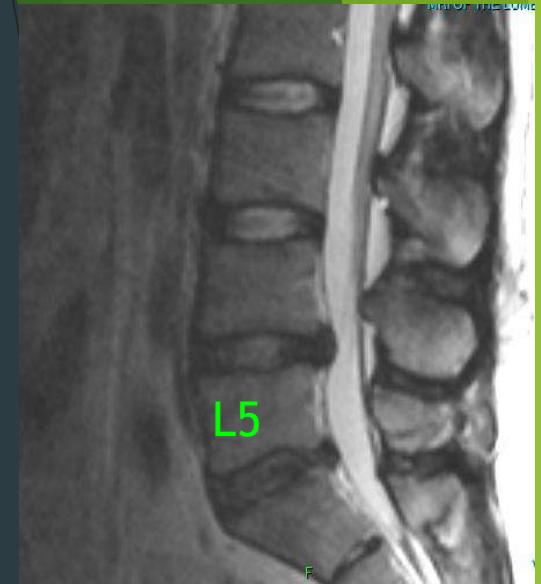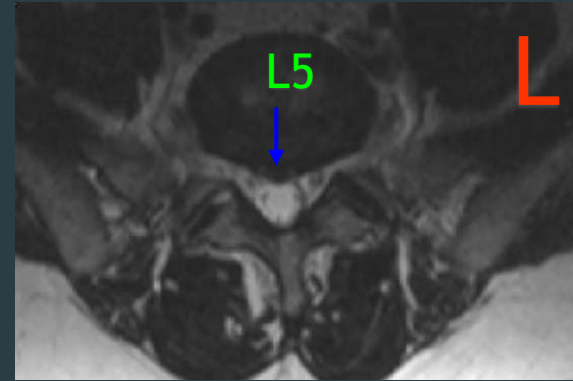
Diagnosis

- ▶ L4-L5: Focal right central disc protrusion is compressing the thecal sac and effacing the bilateral L5 descending nerve roots.
- ▶ Mild spinal canal stenosis.
- ▶ No neural foramina stenosis; normal bilateral L4 exiting nerve roots.
- ▶ It only takes a pressure of a dime on a nerve to be very painful; therefore, effacing a nerve root can cause pain.



Diagnosis

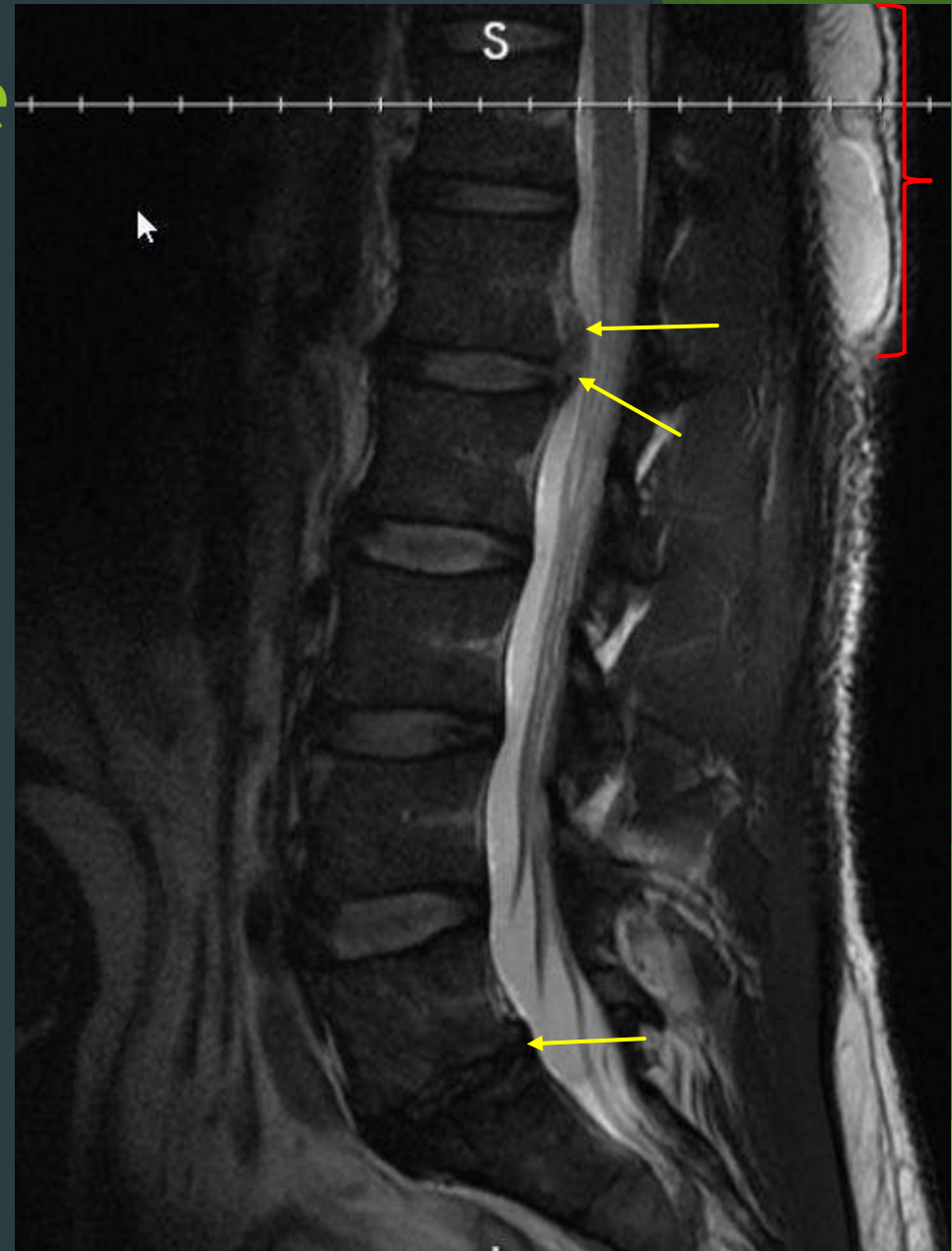
- ▶ L5-S1: Focal central disc protrusion (blue arrow) is effacing the thecal sac and slightly effacing the bilateral L5 descending nerve roots (blue circle).
- ▶ There is no spinal canal or neural foramina stenosis.
- ▶ The L5 exiting nerve roots are normal within the neural foramina.



Case 6: Low back pain following MVA; 45 year-old male.

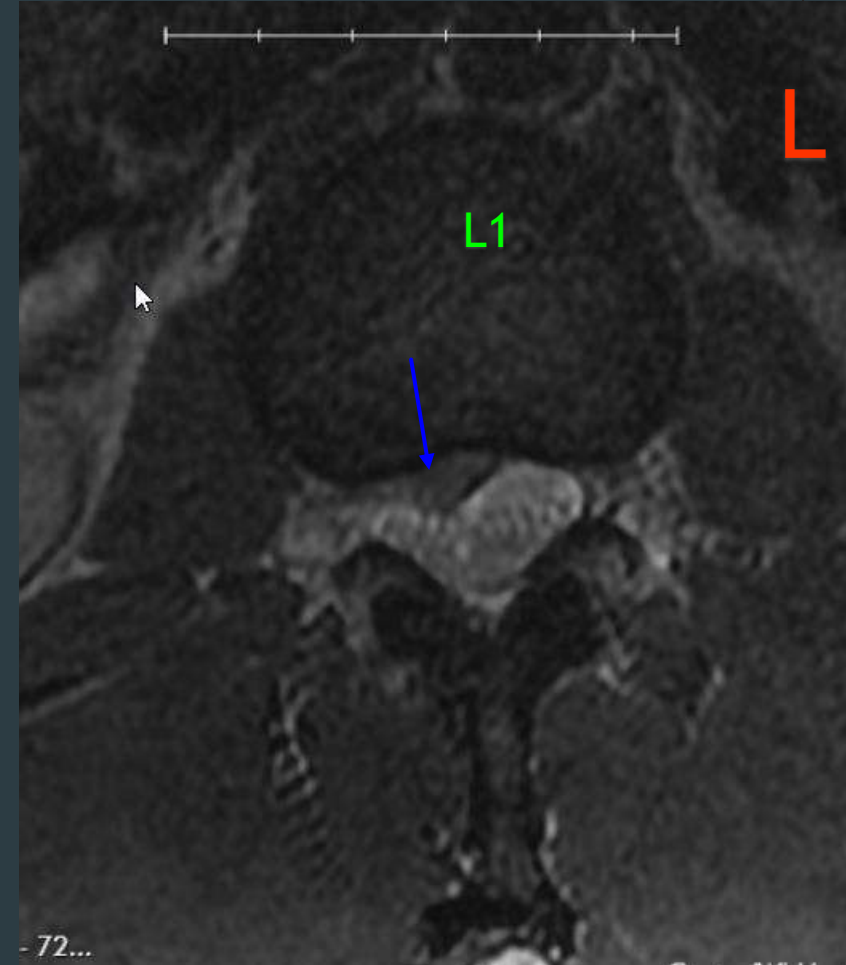
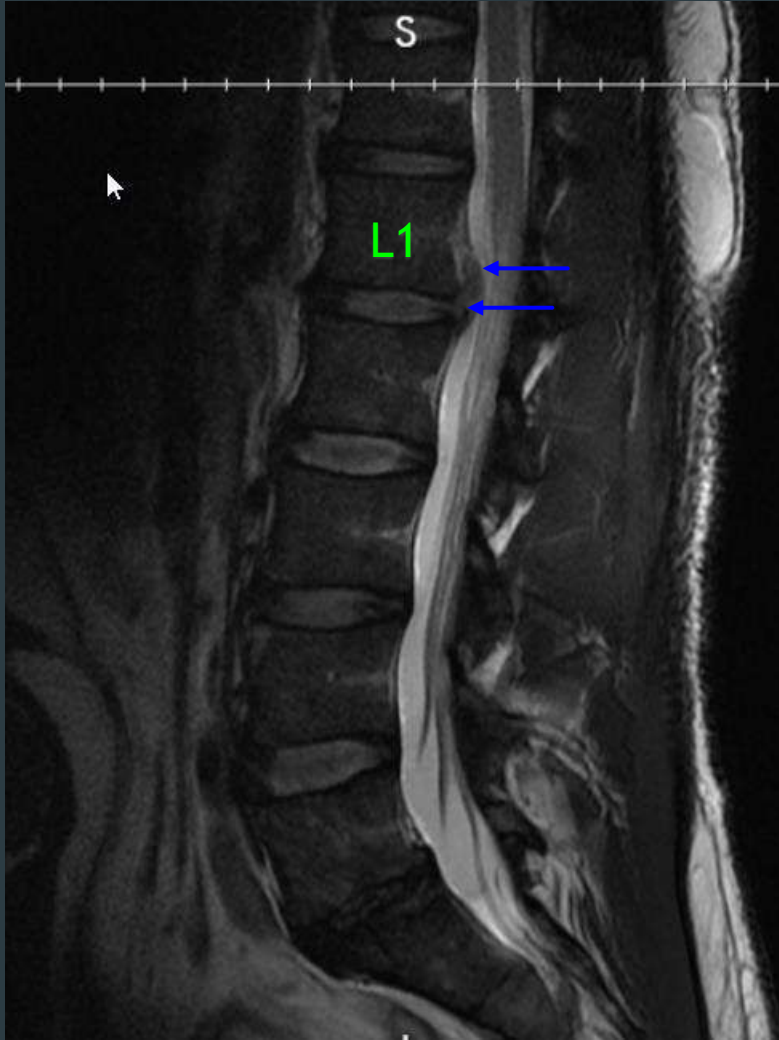
Sagittal T2 weighted image

- Note: Sagittal image is slightly off centered to the right.



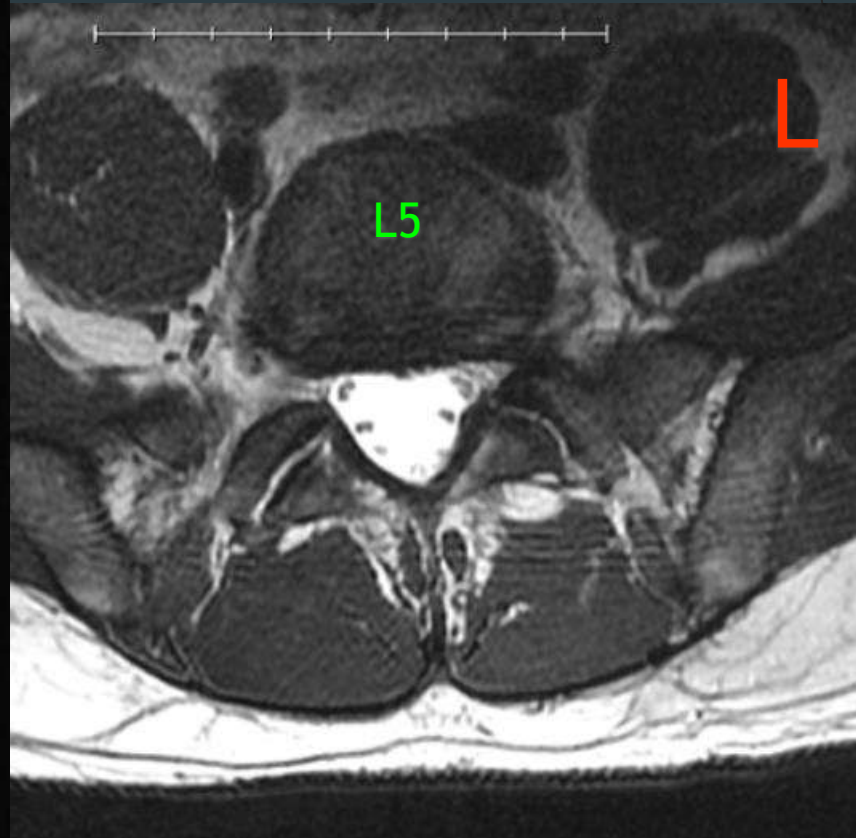
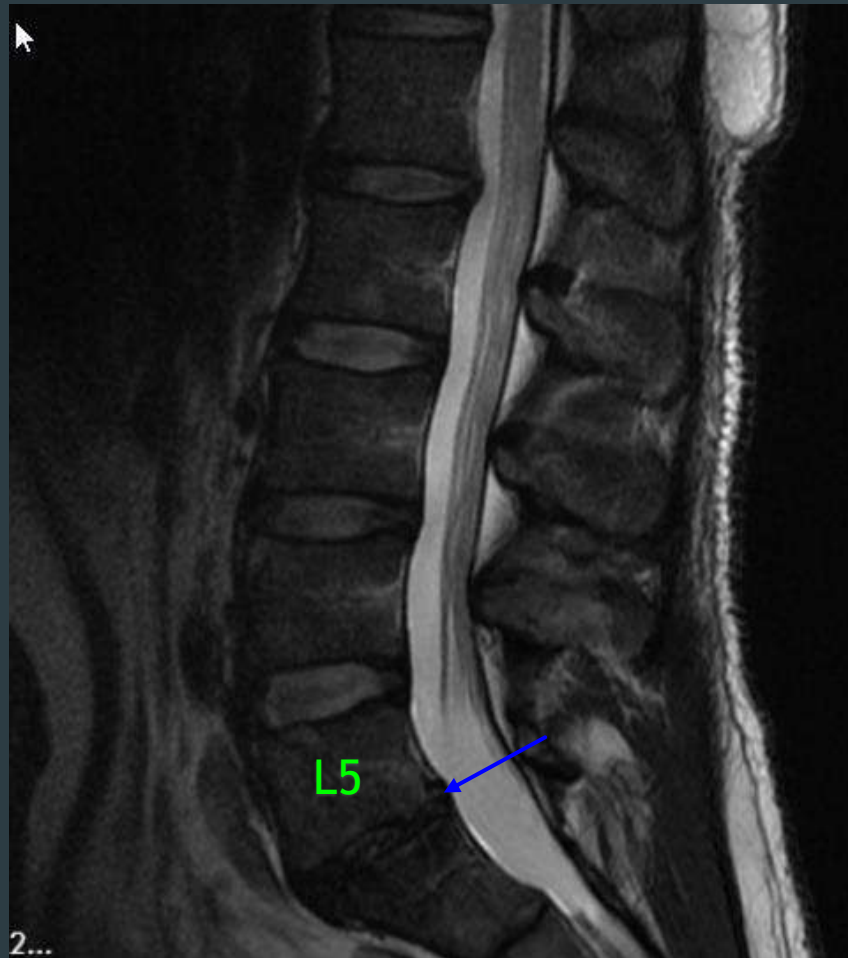
L1

Slightly off centered to right



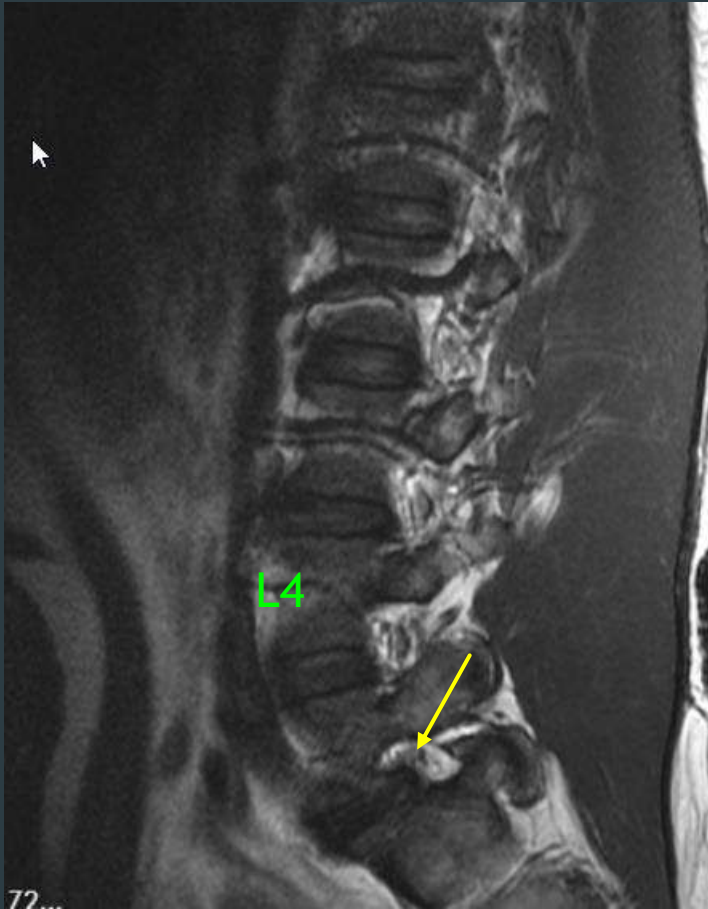
L5

Sagittal image is centered

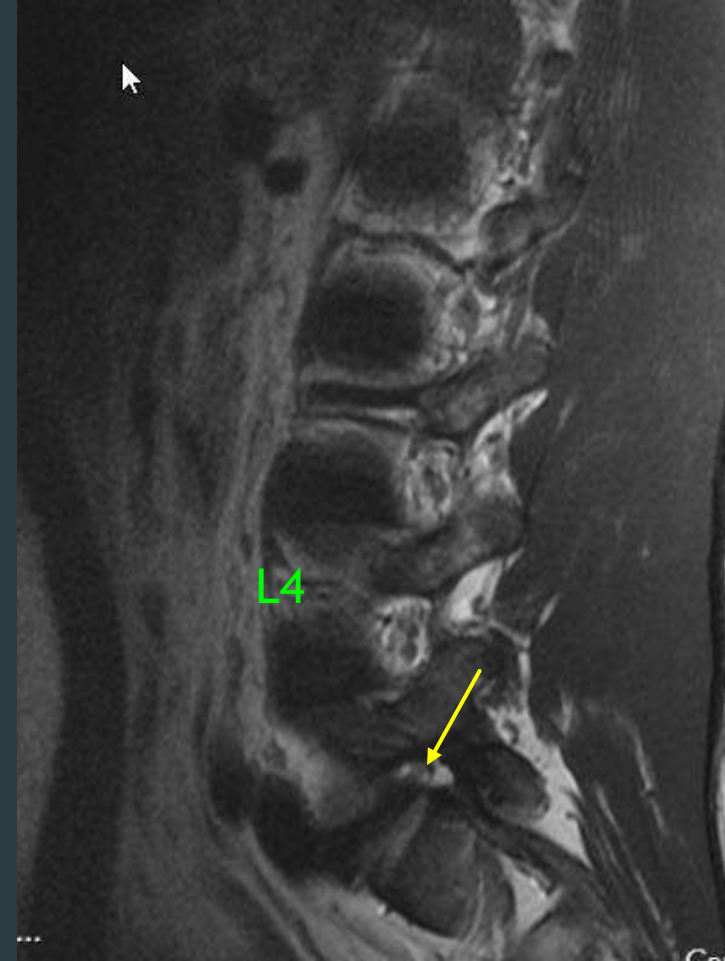

Right/Left Parasagittal

Right Parasagittal

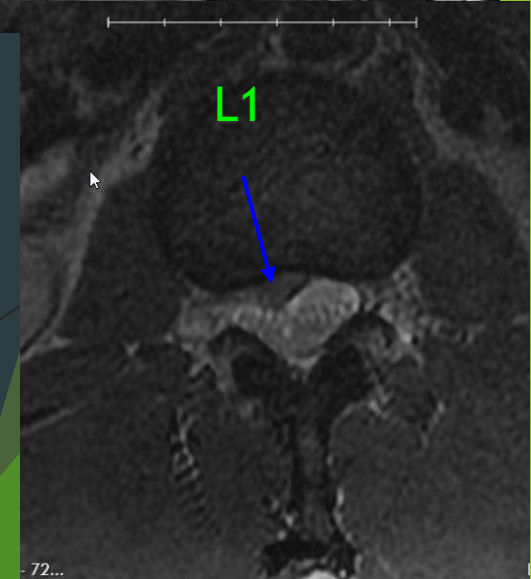
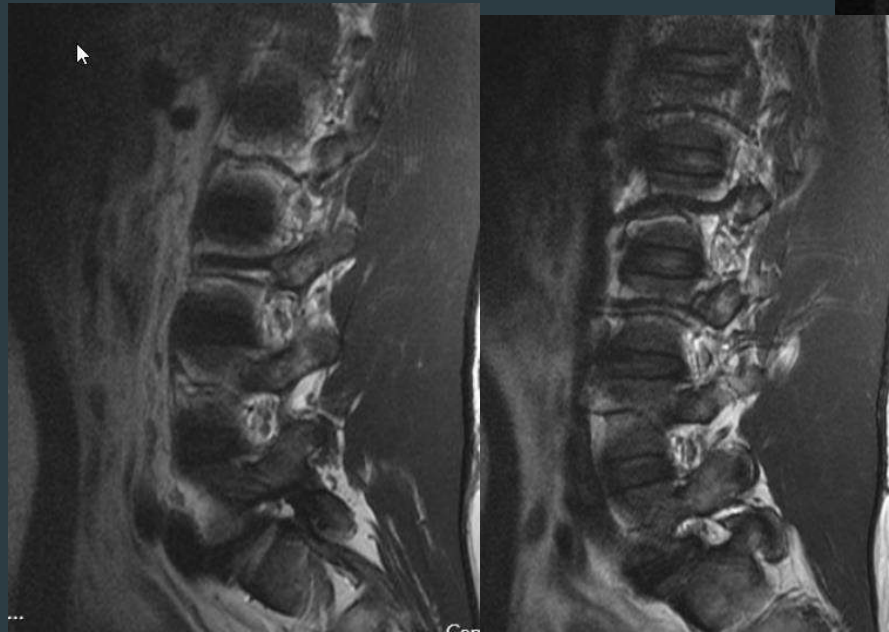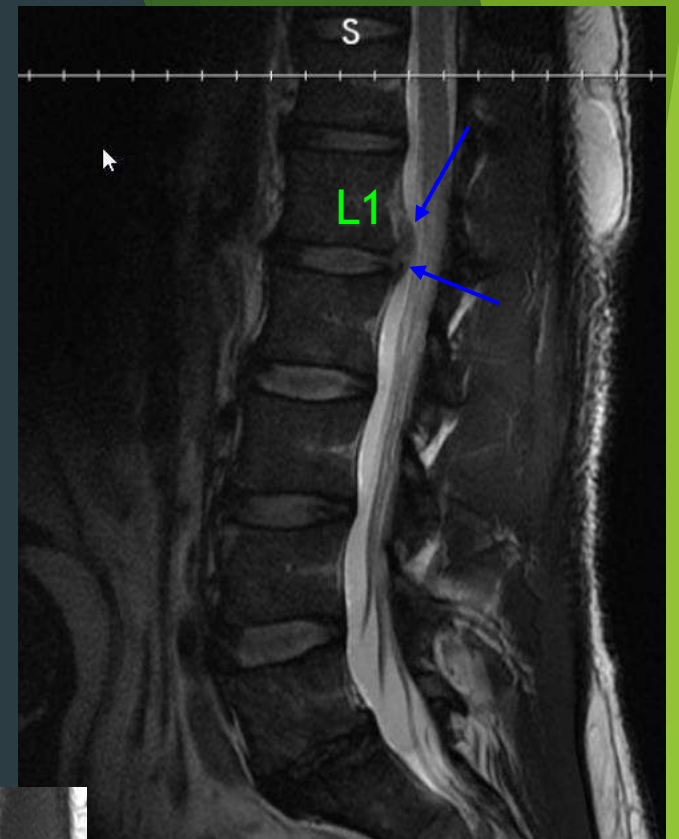


Left Parasagittal



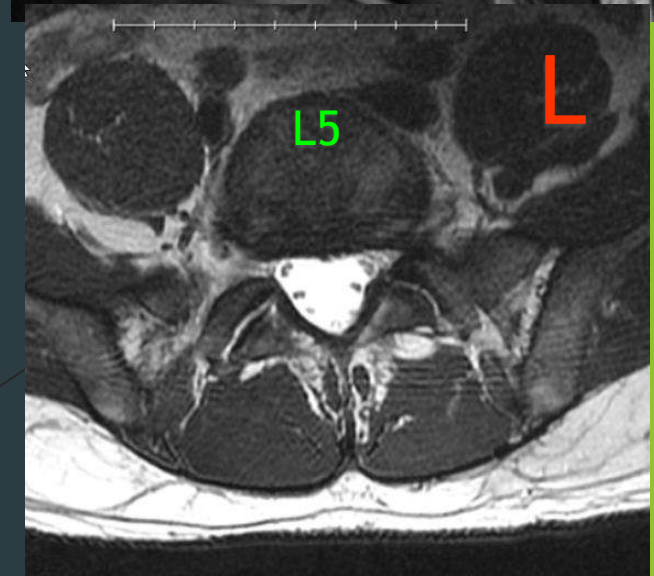
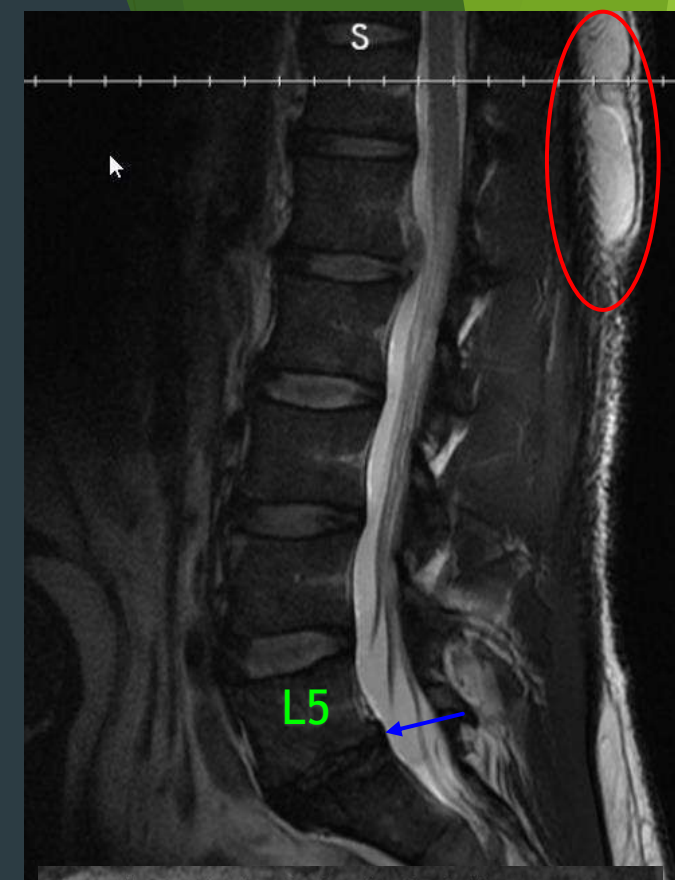
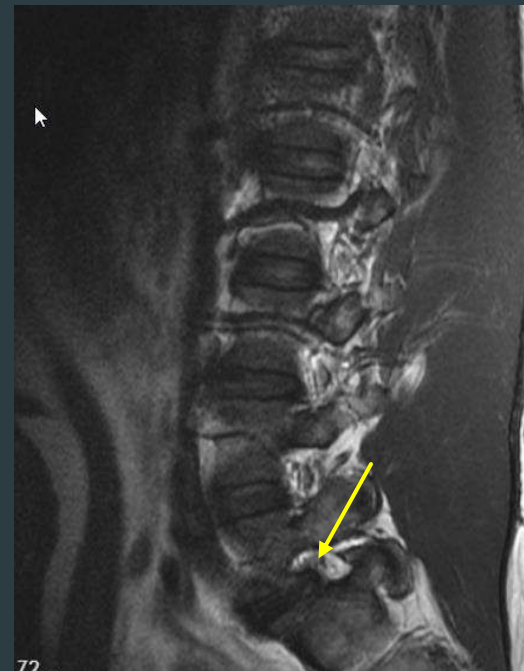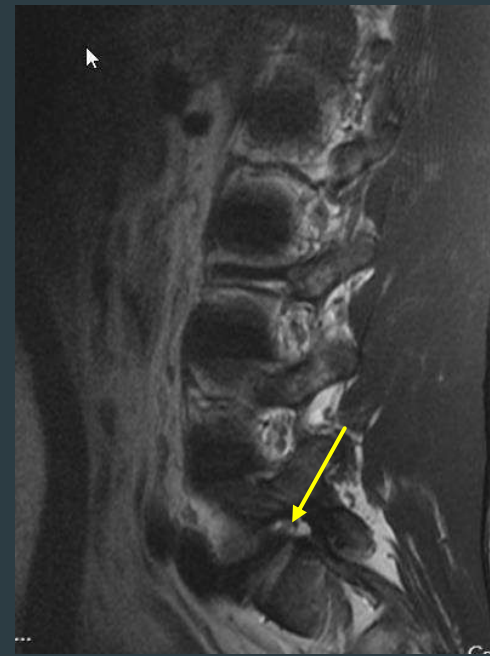Diagnosis

- ▶ L1-L2: Right central disc extrusion (blue arrow) is compressing the thecal sac with cephalad migration and mild spinal canal stenosis.
 - ▶ No neural foramina stenosis; Normal exiting nerve roots.



Diagnosis

- ▶ L5-S1: Diffuse disc bulge (blue arrow) is effacing the thecal sac
 - ▶ Parasagittal images show moderate bilateral neural foramina stenosis with compression to the bilateral L5 exiting nerve roots (yellow arrow), due to the disc bulge, disc narrowing and degenerative anterolisthesis of L5.
 - ▶ Mild bilateral facet arthrosis.
 - ▶ No spinal canal stenosis.
- ▶ Incidentally noted within the posterior soft tissues: Lipomas (red circle). This is a benign fatty tumor. These are palpable.



Treatment for disc bulge/protrusion/extrusion

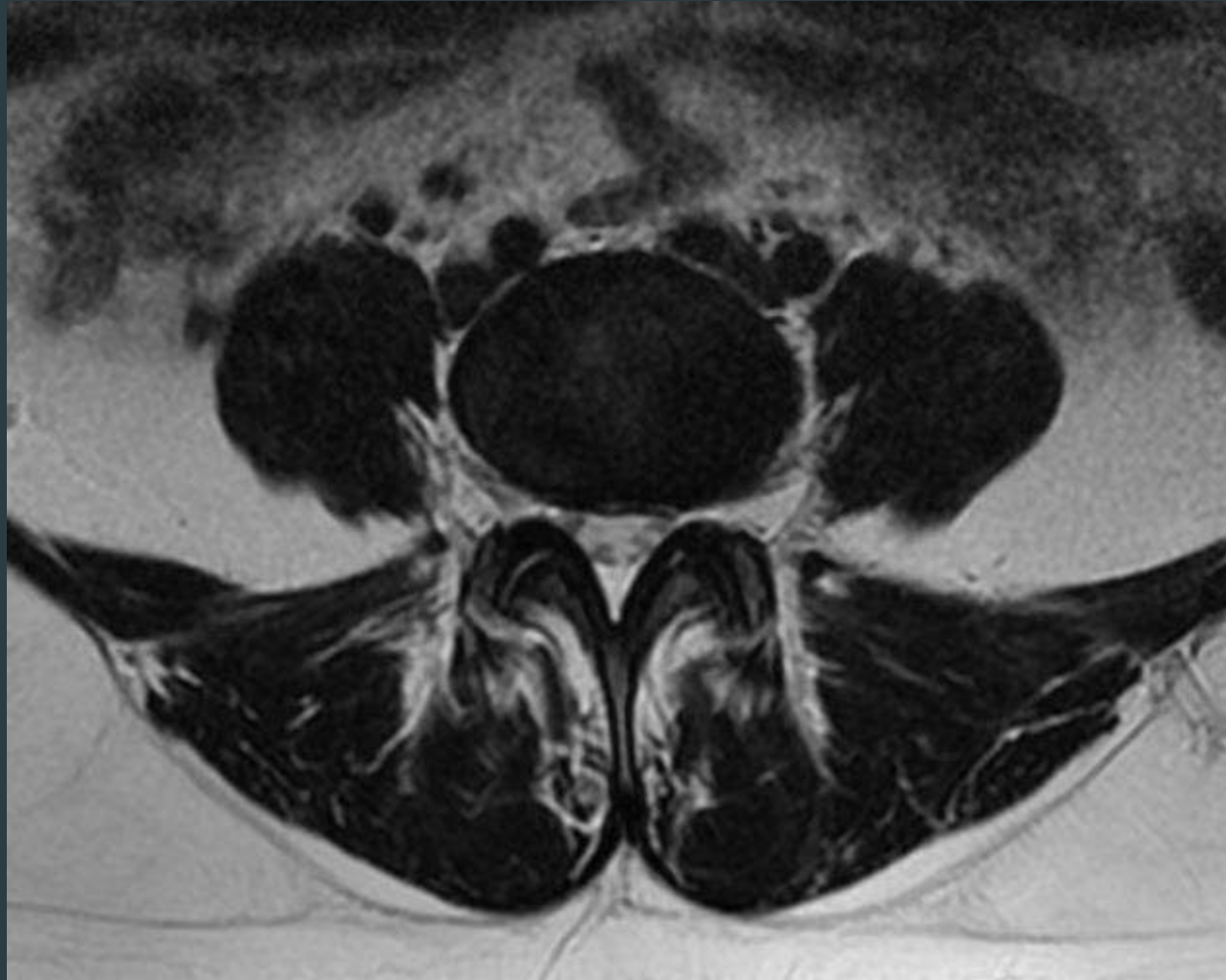
- ▶ Treatment is based on patient tolerance and patient function based on muscle testing, orthopedic and neurology testing. Nonsurgical treatment is what we do!
 - ▶ Yes, you can treat a patient with disc bulge/protrusion/extrusion BUT to patient tolerance.
 - ▶ Manipulation
 - ▶ Cox
 - ▶ Decompression
 - ▶ Kinesio taping
 - ▶ Graston technique
 - ▶ Laser
 - ▶ McKenzie
 - ▶ ETC.!!! Every patient is different, find what works for your patient. Chiropractic can treat spines with disc bulges/protrusions/extrusions.
- ▶ Remember to address inflammation.

Keep in Mind When Viewing Cases or Reading the MRI Report:

- ▶ What type of disc does the patient have or described on the report? Measurements should be used in describing the disc (I don't have measurements throughout the lecture, but I do include measurements on my reports).
- ▶ Where is the disc going..... What is the location of the disc displacement?
- ▶ What is the disc doing to the thecal sac?
- ▶ What is the disc doing to the descending and exiting nerve roots?
- ▶ Is the disc and/or bony structures resulting in spinal canal or neural foramina stenosis? If so, how much? (we can grade stenosis by using mild, moderate or severe).
- ▶ Lastly, do these findings correlate to the clinical findings, patient presentation and/or mechanism of injury?
- ▶ Finally, I hope this lecture was helpful. It is a lot of information😊

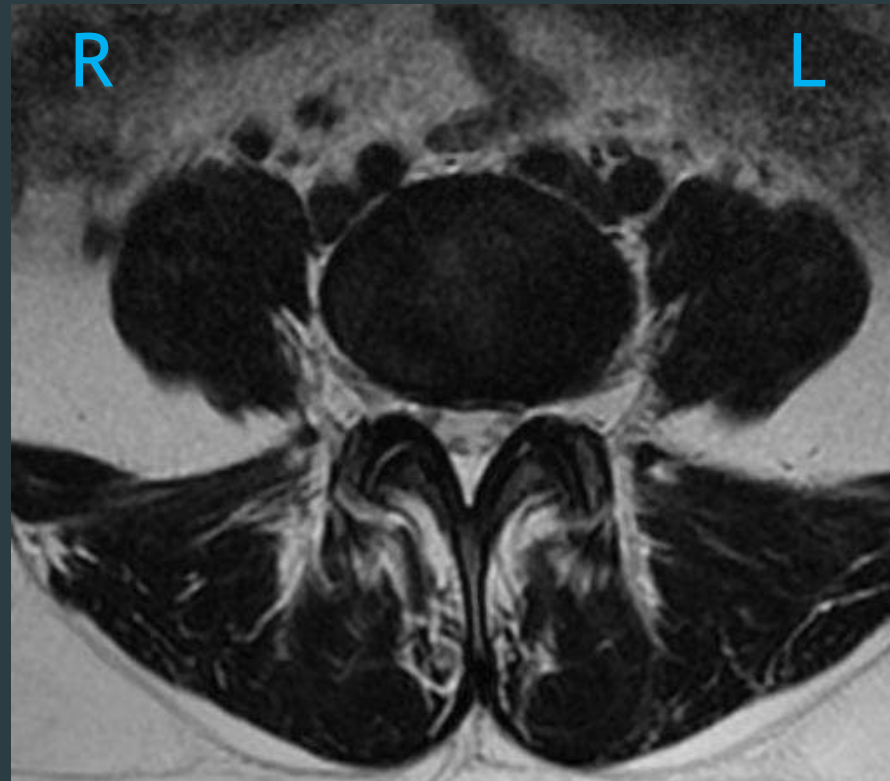
Brief Review of Cases

1

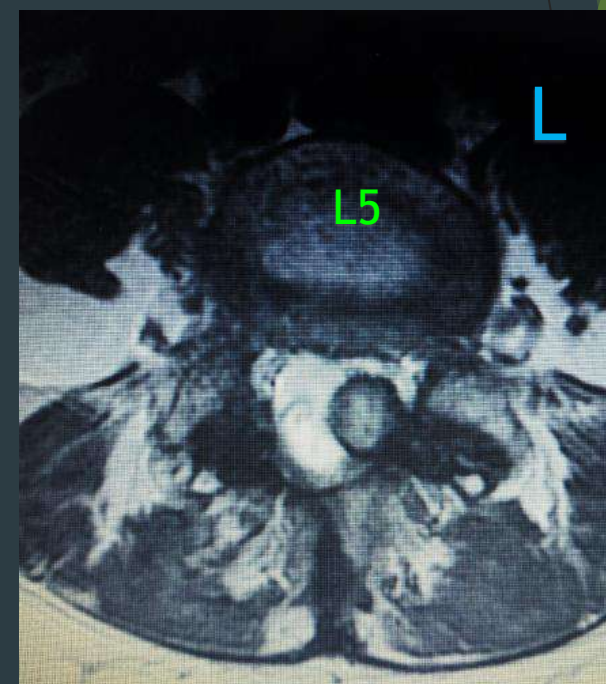
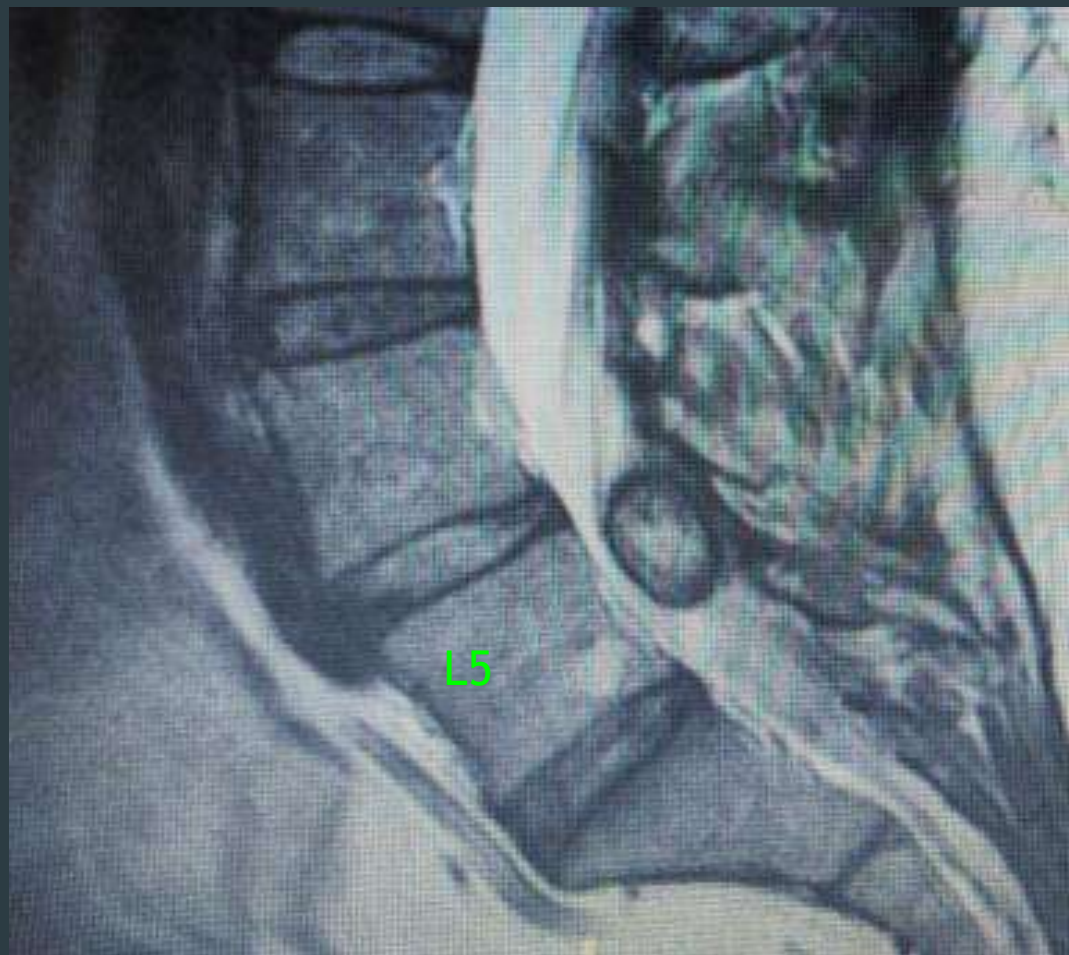

Diagnosis of #1

- ▶ Circumferential disc bulge is compressing the thecal sac with mild spinal canal stenosis; Posterior annular fissure/tear/defect; mild bilateral facet arthrosis.



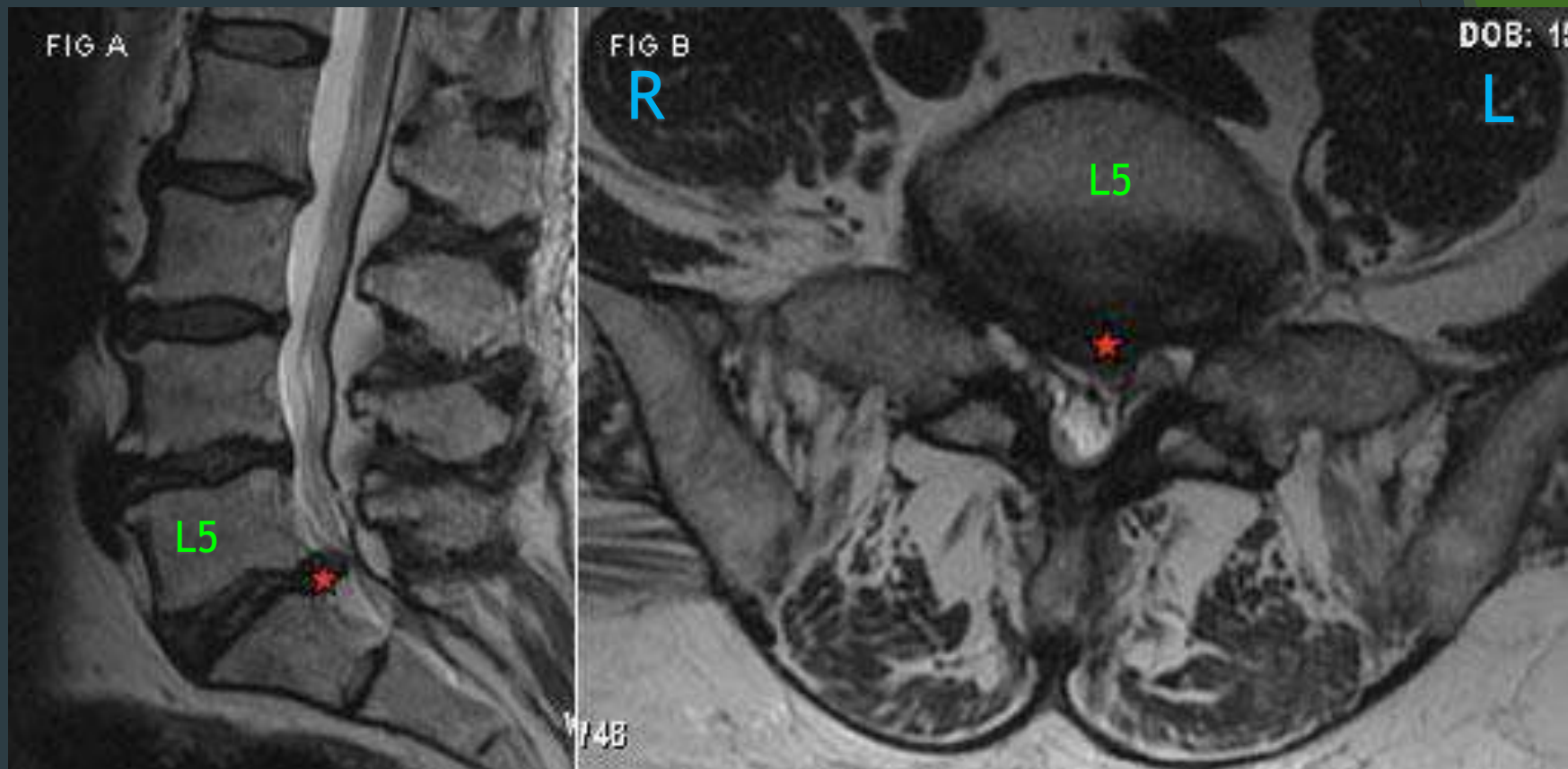
2



Diagnosis of #2

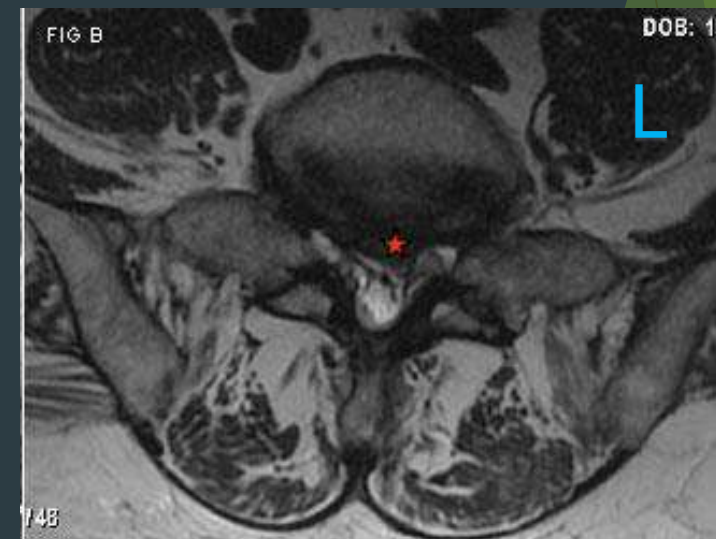
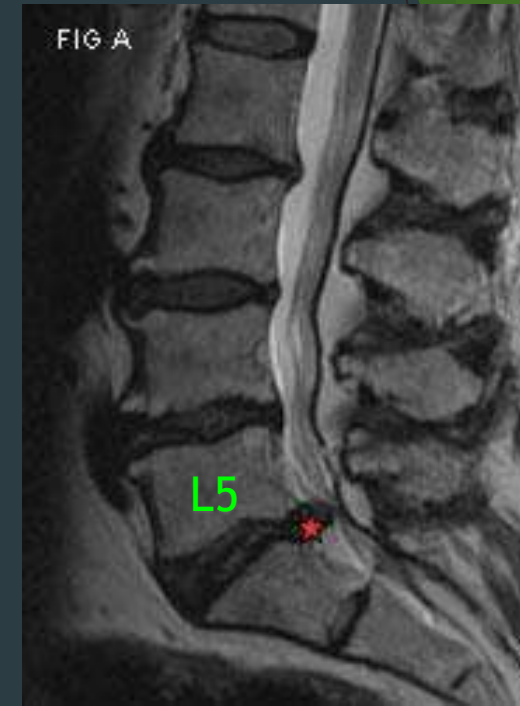- ▶ Left facet cyst- synovial cyst coming from the left facet joint. This is resulting in compression to the thecal sac and severe spinal canal stenosis.
- ▶ Diffuse disc bulge at L4-L5 and L5-S1.
- ▶ Bilateral facet arthrosis.

3

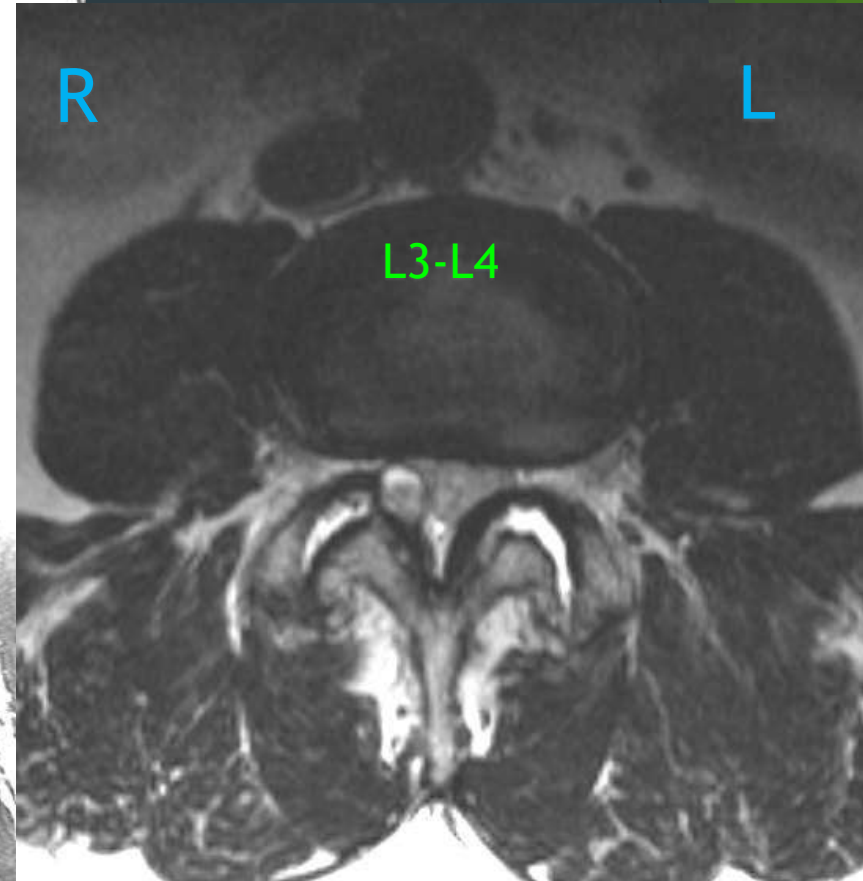
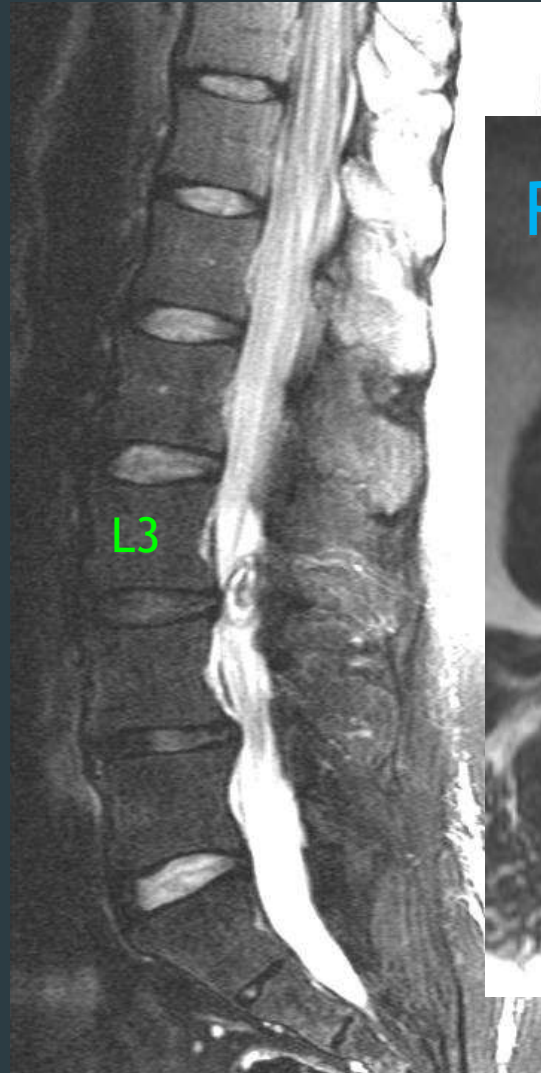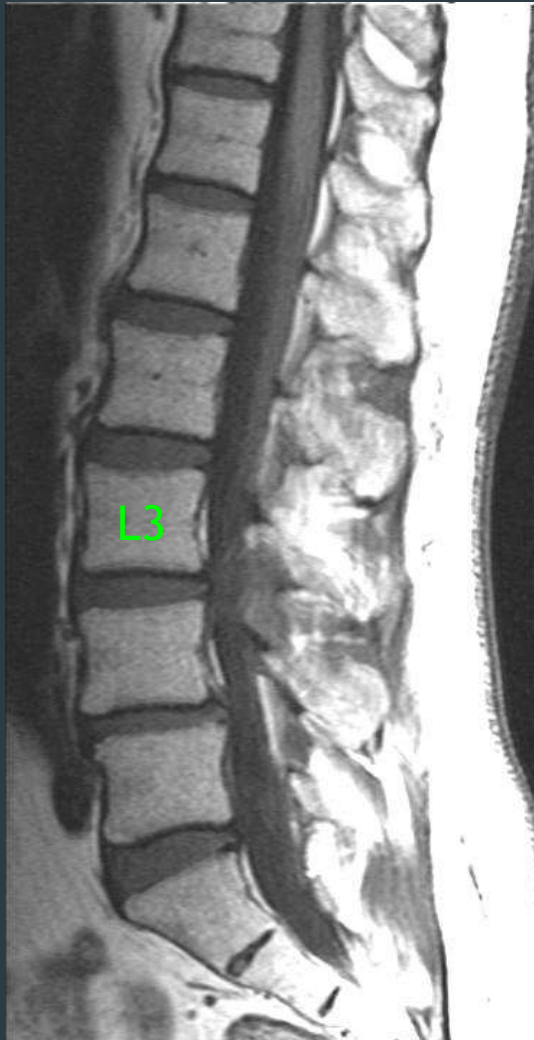


Diagnosis of #3

- ▶ Large left central broad-based disc protrusion versus extrusion at L5-S1, resulting in severe spinal canal stenosis.
- ▶ Compressing and displacing the thecal sac and left descending S1 nerve root
- ▶ Fatty infiltration of the posterior musculature
- ▶ Bilateral facet arthrosis
- ▶ Multilevel degenerative disc disease

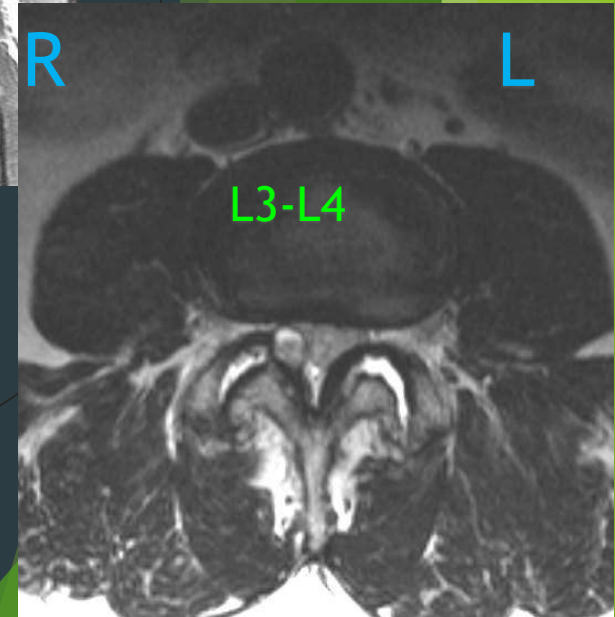
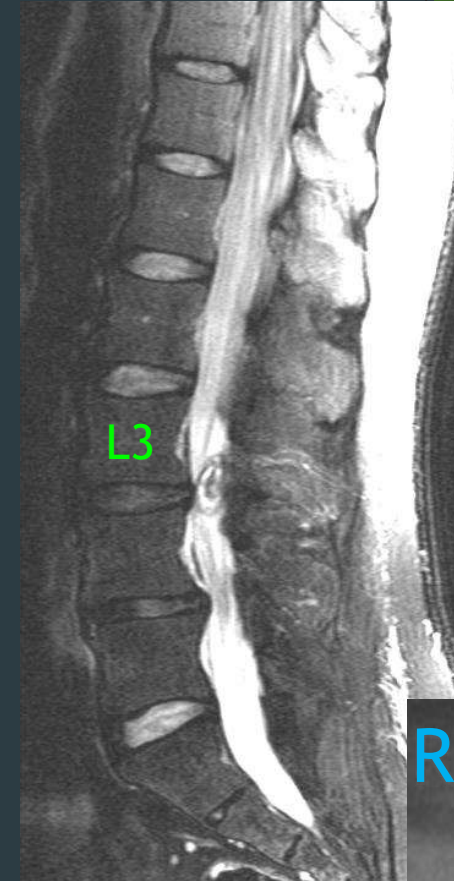

4

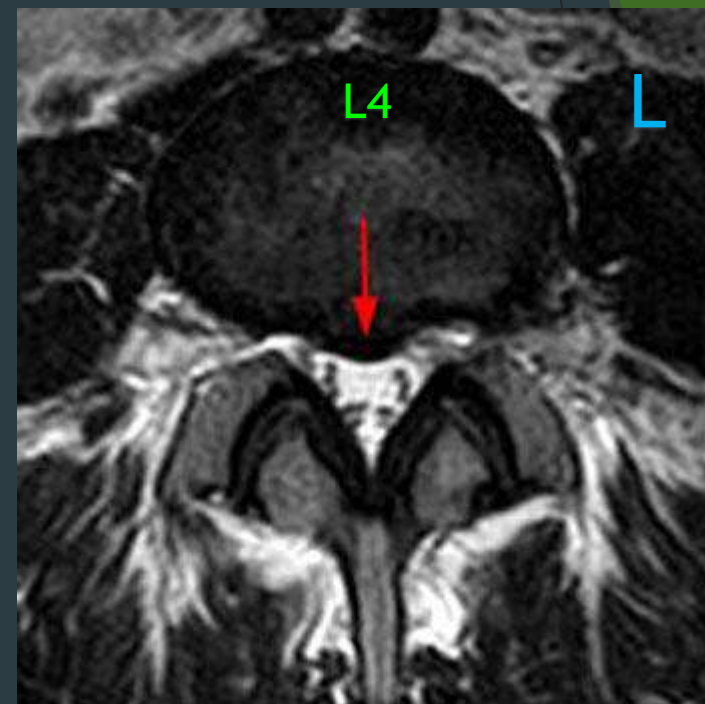
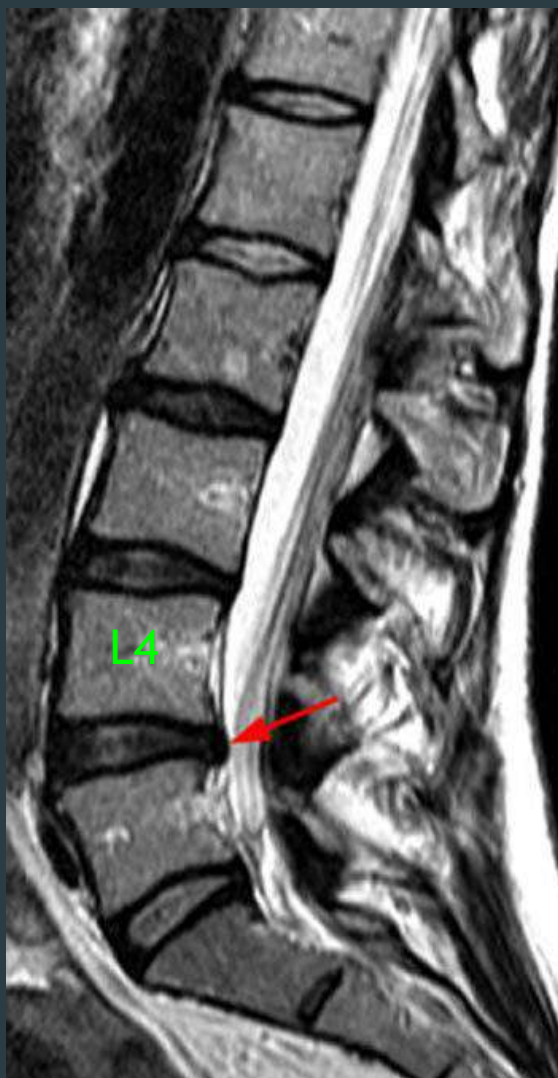


Diagnosis of #4

- ▶ Right synovial cyst or facet cyst with compression of the thecal sac on the left; Severe facet arthrosis.
- ▶ Degenerative anterolisthesis at L4.
- ▶ Diffuse disc bulge L3-L4 and L4-L5 is compressing thecal sac; disc dehydration at L3-L4 and L4-L5.
- ▶ L3-L4: Disc bulge, severe bilateral facet arthrosis, ligamentum flavum hypertrophy and the right synovial/facet cyst are all contributing to severe spinal canal stenosis.

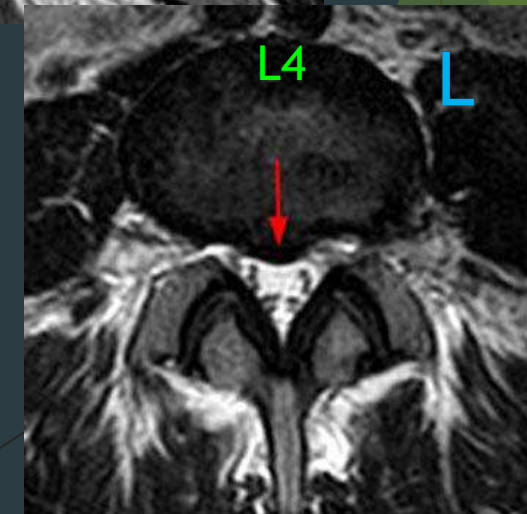
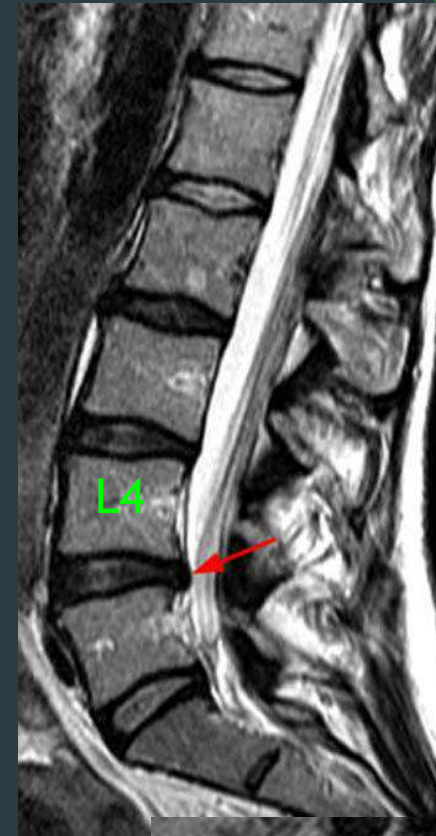

5

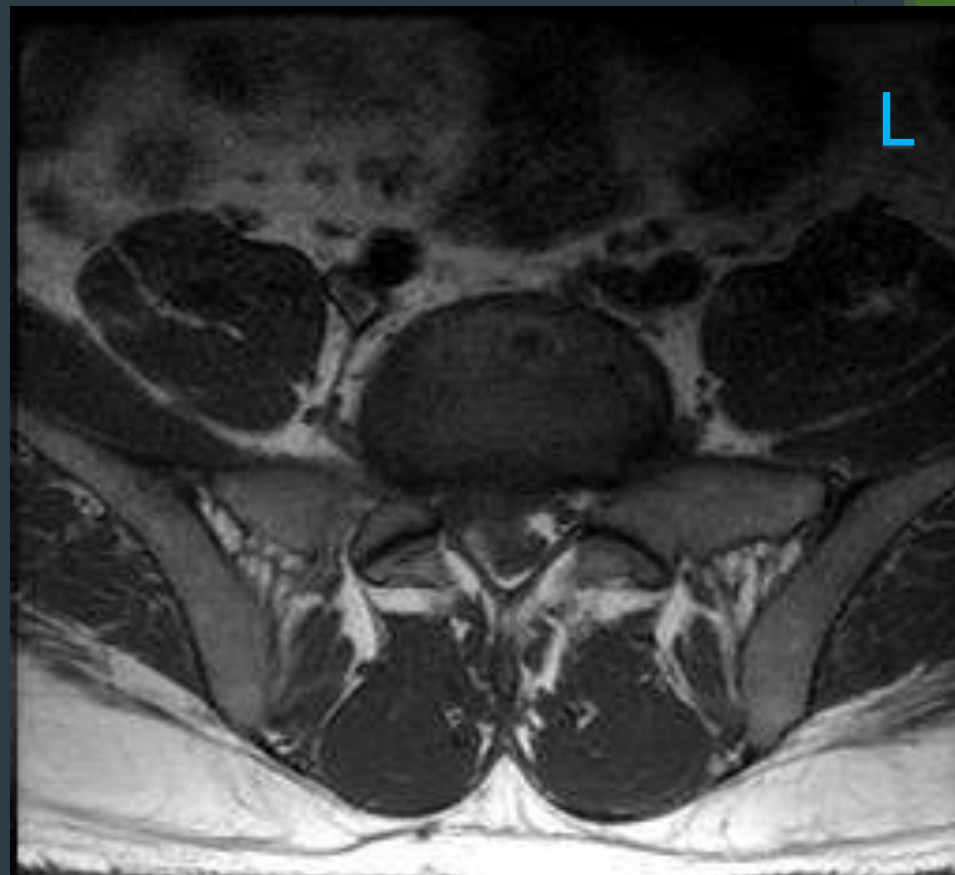
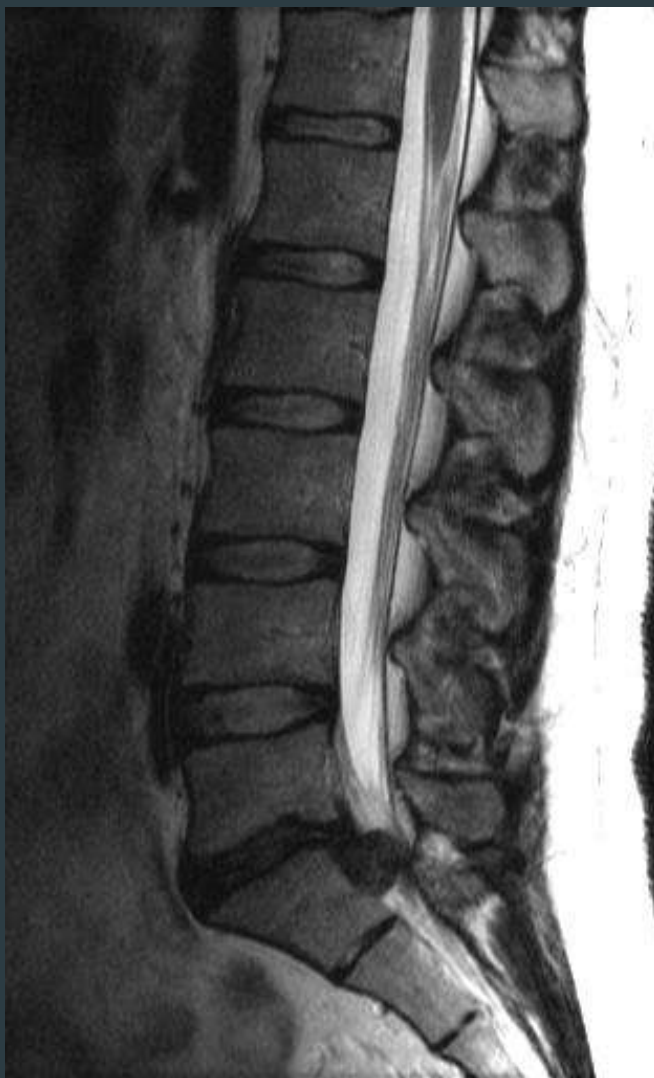

Diagnosis of #5

- ▶ L4-L5: Focal central disc protrusion is compressing the thecal sac with mild spinal canal stenosis.
- ▶ Mild disc desiccation/dehydration at L2-L3, L3-L4 and L4-L5
- ▶ Mild facet arthrosis

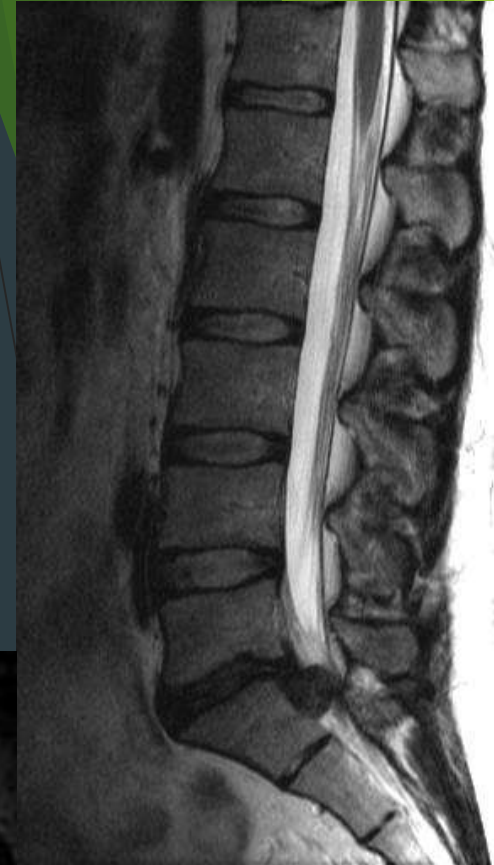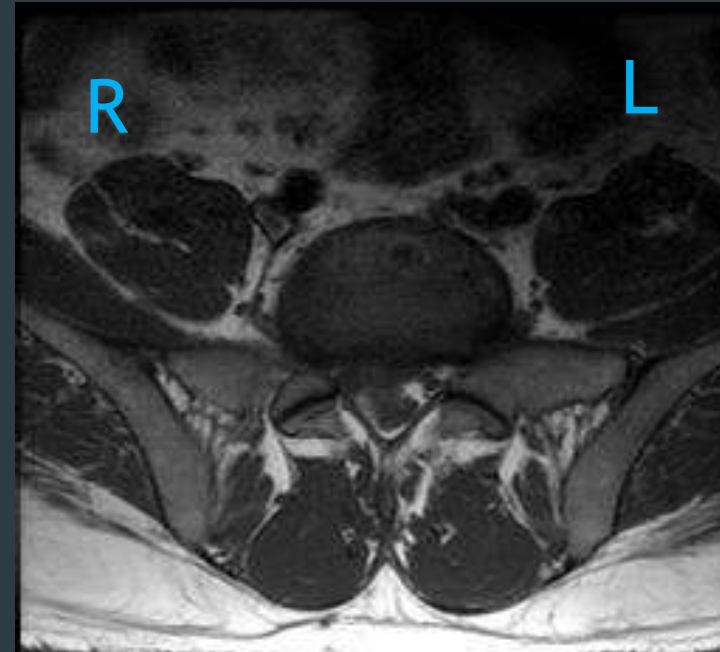


6

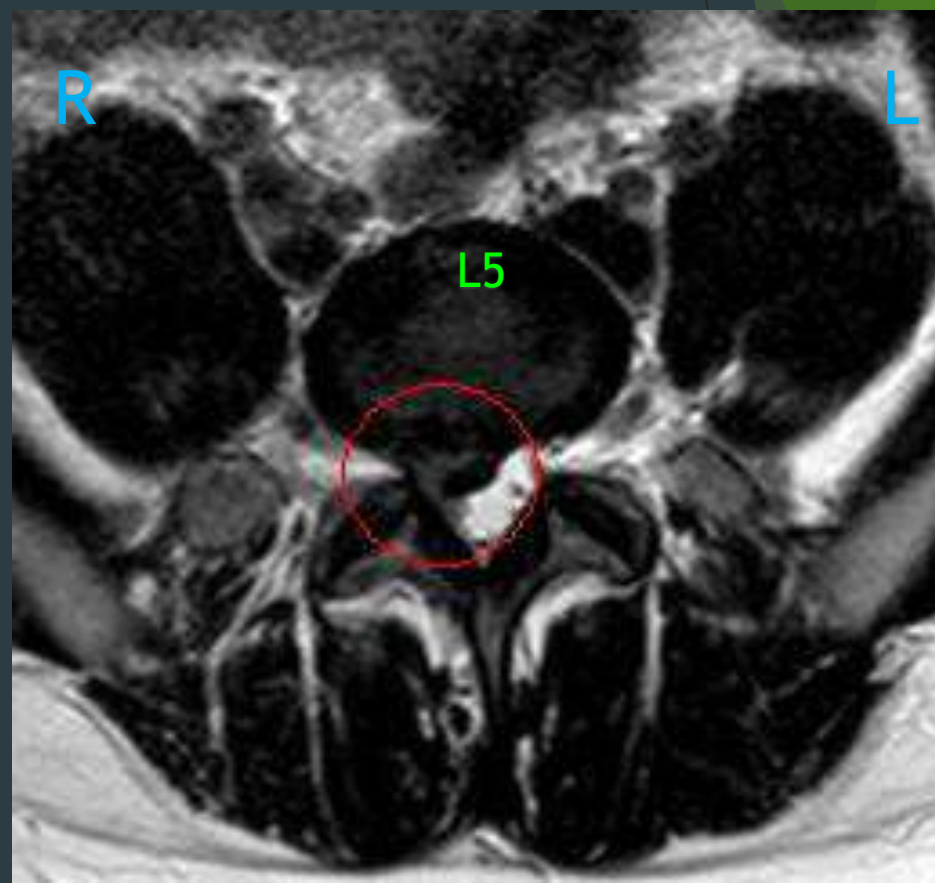
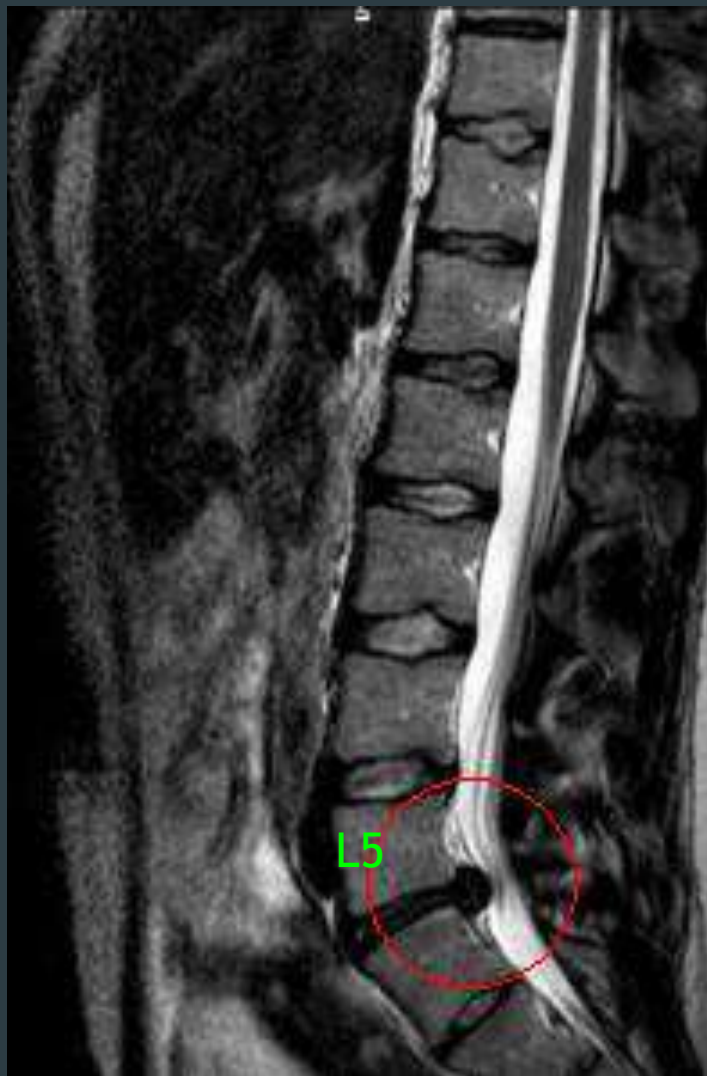

Diagnosis of #6

- ▶ L5-S1: Right central disc extrusion with inferior migration is compressing the thecal sac and right S1 descending nerve roots. There is effacement of the left S1 descending nerve root. Severe spinal canal stenosis is noted.
- ▶ Hypolordosis of the lumbar spine.
- ▶ Disc dehydration and disc narrowing at L5-S1.

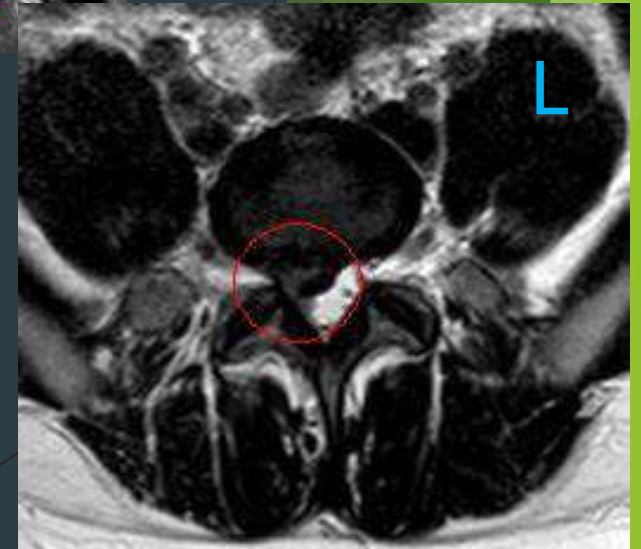
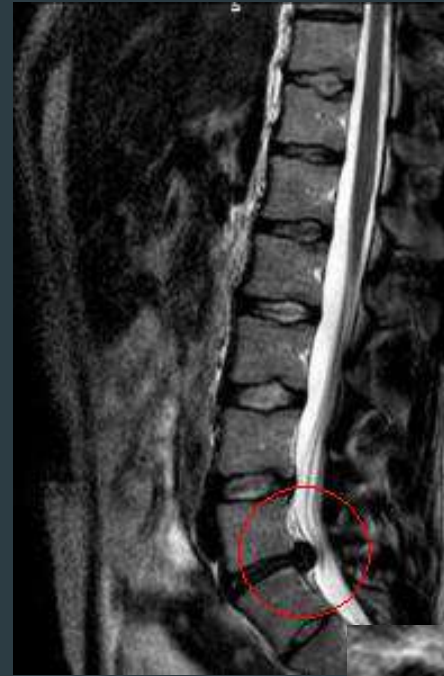

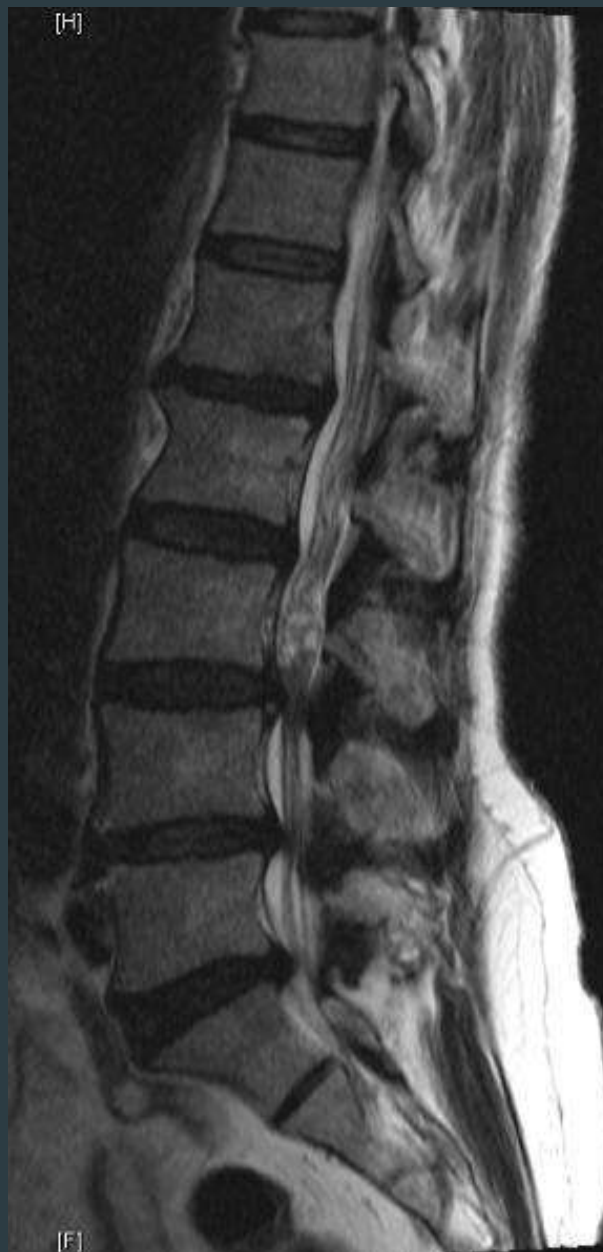7



Diagnosis of #7

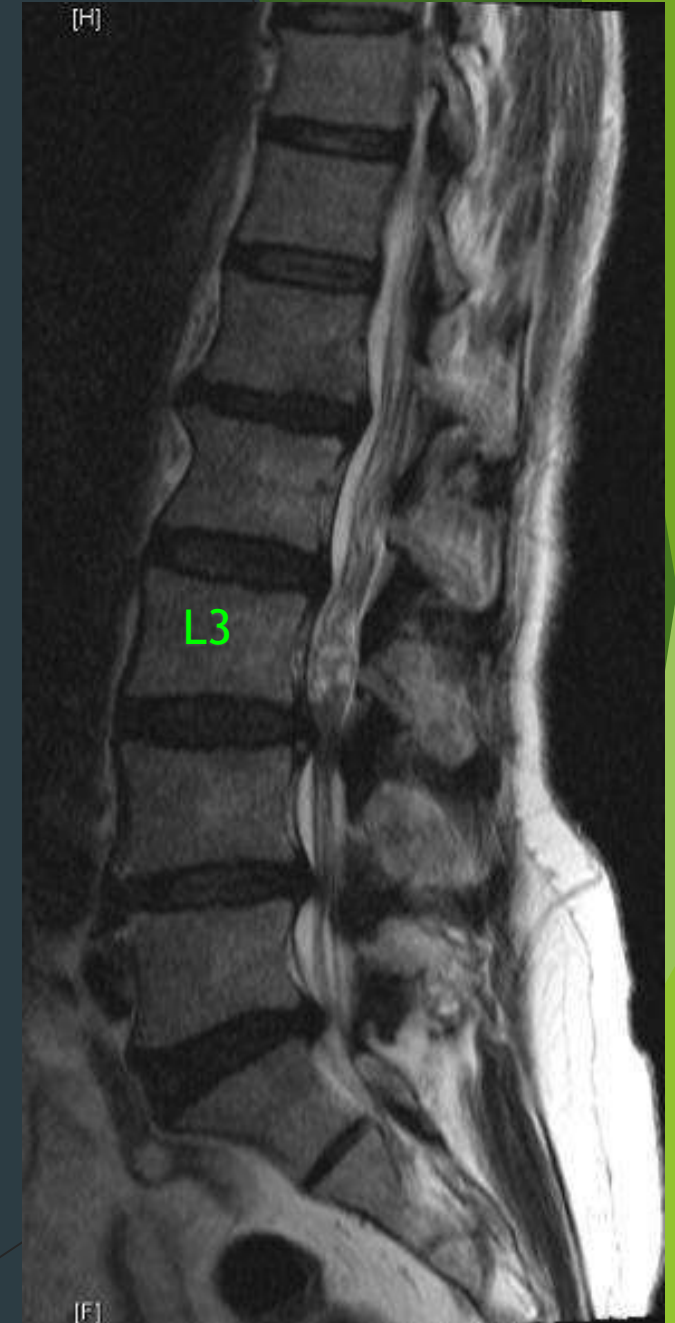- ▶ L5-S1: Right central disc extrusion is compressing the thecal sac and right S1 descending nerve root, resulting in moderate spinal canal stenosis.
- ▶ Mild facet arthrosis at L5-S1
- ▶ Transitional segment with a rudimentary disc at S1.
- ▶ Multilevel Schmorl's node throughout the lumbar spine.





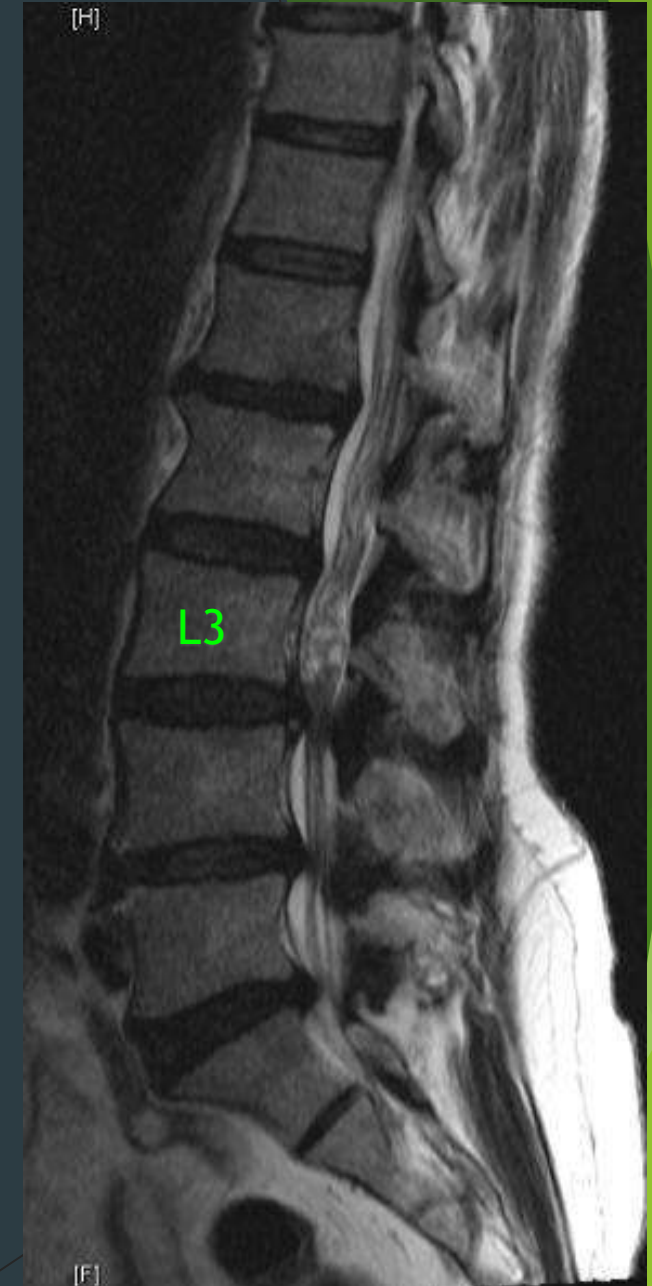
Diagnosis of #8

- ▶ Multilevel disc bulges or protrusions and thickening of the ligamentum flavum at L2, L3 and L4, resulting in severe spinal canal stenosis.
- ▶ Also, there is congenital spinal canal stenosis.
- ▶ Mild degenerative disc disease with disc desiccation and disc narrowing.



Diagnosis of #8

- Irregular contour of the cauda equina at the level of L3 within the spinal canal due to the protrusion and thickening of ligamentum flavum while constricting the thecal sac/cauda equina.



References

- ▶ Fardon D, et al. *Nomenclature and Classification of Lumbar Disc Pathology: version 2*. Spine Journal 14 (2014); 2525-2545.
- ▶ Resnick D. *Diagnosis of Bone and Joint Disorders*, 4th ed. 2002, 1420-1457.
- ▶ Rahme and Moussa. AJNR May 2008 29: 838-842.

www.jprad.com



700 East Redlands Blvd, Redlands CA 92373 909.353.9348 jjpedley39@gmail.com

Thanks for taking CE Seminars with Back To Chiropractic. 😊
I hope you enjoyed the course. Please feel free to provide feedback.

Check out: Back To Chiropractic Resources

Free Materials: Notes & Forms **hundreds of files ~ posters, newsletters & more**

Services & Listings **People helping people for free**

Marcus Strutz DC

Back To Chiropractic CE Seminars

marcusstrutzdc@gmail.com

707.972.0047

